

# Cutaneous Drug Reactions

CRAIG K. SVENSSON,<sup>1</sup> EDWARD W. COWEN, AND ANTHONY A. GASPARI

*Department of Pharmaceutical Sciences, Wayne State University, Detroit, Michigan (C.K.S.); and Department of Dermatology, University of Rochester, Rochester, New York (E.W.C., A.A.G.)*

This paper is available online at <http://pharmrev.aspetjournals.org>

Abstract	357
I. Epidemiology of cutaneous drug reactions	358
II. Clinical morphology of cutaneous drug reactions	358
A. Morbilliform reactions	358
B. Urticaria	359
C. Fixed drug eruption	359
D. Erythema multiforme/Stevens-Johnson syndrome/toxic epidermal necrolysis	361
III. Mechanisms of cutaneous drug reactions	361
A. Immediate-type immune-mediated drug reactions	362
B. Delayed-type immune-mediated drug reactions	363
C. Photosensitivity reactions	366
1. Phototoxicity	367
2. Photoallergy	367
D. Autoimmune syndromes	368
IV. Role of viral infection as a predisposing factor for cutaneous drug reactions	368
V. Cutaneous drug reactions associated with selected drugs	369
A. Sulfonamides	369
B. Anticonvulsants	372
C. Nonsteroidal anti-inflammatory drugs	373
D. Antiretroviral agents	374
E. Cephalosporins	374
F. Ampicillin/amoxicillin	375
Acknowledgments	375
References	375

---

**Abstract**—Cutaneous drug reactions are the most frequently occurring adverse reactions to drugs. Among hospitalized patients, the incidence of these reactions ranges from 1 to 3%. The frequency of cutaneous reactions to specific drugs may exceed 10%. These reactions may range from mildly discomforting to those that are life-threatening. Anti-infective and anticonvulsant agents are among the drugs most commonly associated with adverse reactions in the skin. We describe and illustrate the clinical morphology of the most common cutaneous drug reactions, as well as drugs that most commonly precipitate specific reactions. The varied nature of the reactions that do occur, even with specific agents, indicates a multiplicity of mechanisms available whereby cutaneous drug reac-

tions may be initiated. Although a variety of terms have been proposed for categorizing cutaneous drug reactions, we propose that reactions are best defined based upon mechanisms, where known. In this review, we assess the current knowledge of four categories of cutaneous drug reactions: immediate-type immune-mediated reactions, delayed-type immune-mediated reactions, photosensitivity reactions, and autoimmune syndromes. Moreover, we describe evidence that viral infection is an important predisposing factor for the development of cutaneous drug reactions upon drug administration. Finally, we review the current knowledge of the type and mechanisms of cutaneous drug reactions to several categories of drugs.

---

<sup>1</sup> Address for correspondence: Dr. Craig K. Svensson, Department of Pharmaceutical Sciences, Wayne State University, Detroit, MI 48202. E-mail: [cks@wizard.pharm.wayne.edu](mailto:cks@wizard.pharm.wayne.edu)

## I. Epidemiology of Cutaneous Drug Reactions

Although the true incidence of adverse drug reactions (ADRs<sup>2</sup>) is difficult to quantify, there is abundant evidence that cutaneous drug reactions (CDRs) are among the most frequent adverse events in patients receiving drug therapy. In a study examining the incidence of CDRs in spontaneous ADRs reported in Italy, over 30% of all reported ADRs were cutaneous in nature (Naldi et al., 1999). This is higher than other studies, where CDRs comprise 10 to 20% of reported ADRs—still a substantial fraction of all reactions (Stewart et al., 1979; Faich et al., 1987; van der Linden et al., 1998). Differences in methodology for data collection (e.g., spontaneous reporting versus chart review) may explain the variability in reported frequencies.

Among all hospitalized patients, the incidence of CDRs has been found to range from 1 to 3% (Arndt and Jick, 1976; Stewart et al., 1979; Bigby et al., 1986). Numerous risk factors, including infection with the human immunodeficiency virus (Battagay et al., 1989; Coopman and Stern, 1991; Bayard et al., 1992; Spira et al., 1998; Gonzalez-Martin et al., 1999), infectious mononucleosis (Patel, 1967; Pullen et al., 1967; Nazareth et al., 1972; van der Linden et al., 1998), female sex (Bigby et al., 1986; Naldi et al., 1999; Fattinger et al., 2000), and age (Naldi et al., 1999; Ibia et al., 2000), have been identified. The highest reported frequency of CDRs has consistently been found to be with antimicrobial agents, for which there is also limited data regarding the incidence of CDRs in ambulatory patients. In a population of 13,679 Dutch patients who received a prescription for an antimicrobial agent, the frequency of CDRs was approximately 1% (van der Linden et al., 1998). The most frequent reactions were observed in patients receiving a trimethoprim-sulfonamide combination (2.1%), fluoroquinolones (1.6%), and penicillins (1.1%). A higher frequency of CDRs (7.3%) was recently noted in an ambulatory pediatric population receiving penicillins, sulfonamides, or cephalosporins (Ibia et al., 2000). The percentage of children receiving cefaclor, sulfonamides, penicillins, or other cephalosporins who exhibited a rash during treatment was 12.3, 8.5, 7.4, and 2.6%, respectively. The odds ratio of development of a rash was higher in children less than 3 years of age than other groups.

<sup>2</sup> Abbreviations: ADR, adverse drug reaction; AHS, anticonvulsant hypersensitivity syndrome; AIDS, acquired immunodeficiency syndrome; APC, antigen-presenting cells; CDR, cutaneous drug reaction; COX-2, cyclooxygenase-2; CYP450, cytochrome P450; EM, erythema multiforme; GSH, glutathione; HIV, human immunodeficiency virus; HLA, human leukocyte antigen; HSP, heat shock protein; ICAM-1, intercellular adhesion molecule 1; IL, interleukin; MHC, major histocompatibility complex; NSAID, nonsteroidal anti-inflammatory drugs; PCP, *Pneumocystis carinii* pneumonia; SJS, Stevens-Johnson syndrome; SMX, sulfamethoxazole; SMX-NOH, sulfamethoxazole hydroxylamine; TCR, T-cell receptor; TCSA, 3,3',4',5-tetrachlorosalicylanilide; TEN, toxic epidermal necrolysis; TMP, trimethoprim; TNF- $\alpha$ , tumor necrosis factor  $\alpha$ ; UVA, ultraviolet A; UVB, ultraviolet B.

Determination of the true incidence of CDRs is difficult due to imprecise diagnostic criteria. Causality assessment varies among reported studies and is limited by the ethical constraints of rechallenging patients with a drug that may evoke a life-threatening or seriously disabling reaction. As skin rashes can often occur in the presence of bacterial or viral infection in the absence of drug therapy, determination of causality in suspected CDRs with antimicrobial agents is especially problematic. Several studies have suggested that Bayesian approaches may serve as a useful aid in the differential diagnosis of a suspected CDR, but there is no "gold standard" against which to compare such methods for accuracy (Kwok et al., 1994; Lanctot et al., 1994).

Based on the frequency of drug ingestion and the incidence of CDRs for inpatients from the Boston Collaborative Drug Surveillance Program, Levenson and colleagues (1991) estimated in 1991 that 2.25 million patients in the United States experience CDRs each year. As the frequency of drug ingestion has significantly increased since that date, the anticipated number of patients experiencing such reactions is considerably higher than this previous estimate. Because it has recently been estimated that between 5 and 9% of all hospital costs are related to ADRs (Moore et al., 1998), CDRs clearly represent a significant burden on the health care system, in addition to being a frequent reason for cessation of otherwise effective drug therapy in patients.

## II. Clinical Morphology of Cutaneous Drug Reactions

### A. Morbilliform Reactions

Morbilliform rashes are common CDRs characterized by primary skin lesions of fine pink macules and papules that may become confluent. Typically, lesions begin on the trunk and pressure-bearing areas and progress symmetrically to cover large areas of the body (Fig. 1). Lesions usually begin within 1 to 2 weeks of starting a medication and fade 1 to 2 weeks following cessation.

Histologic examination reveals a lymphocytic interface dermatitis with vacuolar changes at the dermal-epidermal junction and papillary dermal edema and eosinophils. Dyskeratotic cells may be found along the dermal-epidermal junction (Crowson and Magro, 1999).

Because CDRs, particularly morbilliform reactions, are so common and because they may be seen with many different classes of medications, identification of the causative agent can be a significant challenge (Table 1) (Breathnach, 1998; Crowson and Magro, 1999). Roujeau and Stern (1994) describe several criteria that may be helpful in defining a CDR: 1) other causes for the eruption, such as viral exanthem, should be excluded; 2) a temporal relationship between drug use and onset of the rash should exist; 3) improvement should be noted following drug cessation; 4) reactivation upon rechallenge

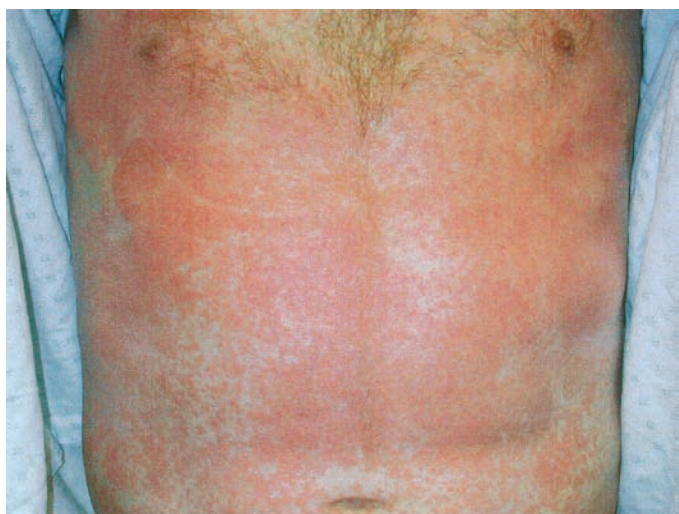

FIG. 1. Morbilliform eruption. The patient developed a pruritic maculo-papular eruption on the torso after receiving trimethoprim-sulfamethoxazole.

of the drug should be noted; and 5) the cutaneous reaction is known to be associated with the drug in question. *Drug Eruption Reference Manual* (Litt, 1999) is an excellent source of detailed listings of the reported type and frequency of eruptions associated with a particular medication.

A careful history and research into the causative agent will allow prompt withdrawal of the offending agent and can prevent a patient from being falsely labeled with multiple drug allergies. There is some evidence that certain individuals are more likely to develop reactions to multiple medications, but a "multiple drug allergy syndrome" has not been clearly established (Gruchalla, 2000). The labeling of patients with multiple drug allergies to antibiotics may be contributing to the overuse of broad-spectrum antibiotics and increasing drug resistance.

### B. Urticaria

Urticaria is the second most common CDR (Table 1) (Breathnach, 1998). The hallmark features of an urticarial eruption are the development of pink wheals on the skin with accompanying pruritus. Angioedema is the corresponding tissue reaction of urticaria occurring deeper in the subcutaneous tissue. The clinical appearance of drug-induced urticaria is indistinguishable from urticaria attributable to other causes. The pruritic wheals of urticaria arise as edematous plaques that may range from red to flesh-colored to yellow (Fig. 2). Follicular prominence may be increased as the hair follicles are anchored deeply in the dermis below the tissue edema. As lesions progress, a raised annular or serpiginous border with central clearing may be seen. As a rule, single lesions last less than 24 h, although new lesions may continue to arise. In contrast, angioedema is characterized by deep, skin-colored swelling, most commonly of the lips or eyes, that may last for several days.

It may occur with urticarial lesions or arise independently.

The histology of an urticarial drug reaction is indistinguishable from that of urticaria from other causes. Interstitial dermal edema with endothelial swelling is present with variable infiltrate of lymphocytes, neutrophils, and eosinophils in the dermis.

Urticarial vasculitis is a distinct small-vessel vasculitic disease that should be differentiated from urticaria. It is characterized by painful rather than pruritic urticarial skin lesions that persist for greater than 24 h and usually resolve with postinflammatory pigmentation. Systemic findings are also common and include arthritis and abdominal or chest pain. Most cases of urticarial vasculitis are idiopathic but it may be associated with collagen vascular disease and viral infection (Odom et al., 2000).

### C. Fixed Drug Eruption

Fixed drug eruption represents a unique CDR pattern characterized by skin lesion(s) that recur at the same anatomic site(s) upon repeated exposures to an offending agent. Most commonly, the skin lesion is a dusky erythematous macule and is usually found on the lips and genitalia, although any skin or mucosal surface may be involved. The skin lesions may be associated with a burning sensation and may be present in multiple numbers or progress to the development of central vesicles and bullae, particularly after the repeated use of an agent (Fig. 3). The skin findings may be associated with nonspecific constitutional symptoms, including fever, malaise, nausea, and vomiting.

Fixed drug eruption usually occurs within hours of administration of the offending agent. Most commonly implicated are sulfa medications, barbiturates, and tetracycline, although many different medications have been implicated (Table 1) (Crowson and Magro, 1999; Stern and Wintroub, 1999). Certain medications also appear to have a predilection for certain anatomic locations (e.g., tetracyclines: genitalia).

Histology demonstrates a mixed inflammatory infiltrate of lymphocytes, neutrophils, and eosinophils at the dermal-epidermal junction. The epidermis contains necrotic keratinocytes. Melanin-containing macrophages in the dermis and chronic epidermal changes including acanthosis, hypergranulosis, and hyperkeratosis may be seen in older lesions (Crowson and Magro, 1999).

The differential diagnosis of fixed drug eruption includes erythema multiforme (EM), as well as Stevens-Johnson syndrome (SJS) and toxic epidermal necrolysis (TEN), in cases of disseminated or bullous fixed drug eruption. In contrast to fixed drug eruption, recurrent lesions in EM tend not to recur in the sites of previous involvement (Sowden and Smith, 1990). Unlike SJS and TEN, mucous membrane involvement is not a consistent finding in fixed drug eruption.

TABLE 1  
*Drugs commonly associated with various CDR*

MDE	Urticaria	FDE	SJS/TEN
Allopurinol	ACE inhibitors	Allopurinol	Allopurinol
Amphotericin B	Aminoglycosides	Barbiturates	Amoxicillin
Barbiturates	Azole antifungals	Dapsone	Ampicillin
Benzodiazepines	Cephalosporins	NSAIDs	Barbiturates
Captopril	Hydralazine	Oral contraceptives	Carbamazepine
Carbamazepine	Narcotic analgesics	Metronidazole	Diclofenac
Gold	NSAIDs	Pseudoephedrine	Nevirapine
Lithium	Penicillin and its derivatives	Sulfonamides	Nitrofurantoin
NSAIDs	Phenytoin	Tetracycline	Phenobarbital
Penicillin and its derivatives	Quinidine		Phenytoin
Phenothiazines	Protamine		Piroxicam
Phenytoin	Salicylates		Sulfonamides
Quinidine	Sulfonamides		
Sulfonamides	Tetracyclines		
Thiazides			

ACE, angiotensin-converting enzyme; FDE, fixed drug eruption; MDE, morbilliform drug eruption.

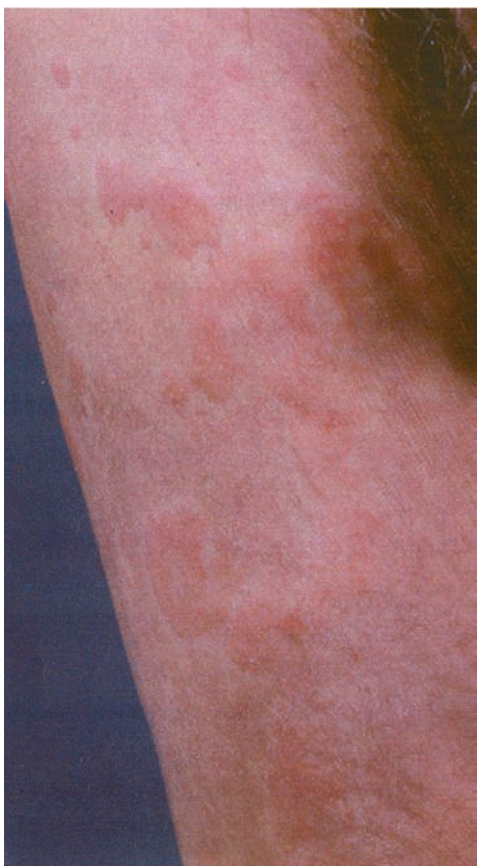

FIG. 2. Acute generalized urticaria secondary to ampicillin. The patient was receiving the antibiotic to treat a urinary tract infection. Depicted area is the anterior thigh.

Fixed drug eruptions resolve spontaneously without scarring a few weeks after onset, usually with residual postinflammatory pigmentation. A non-pigmenting variant of fixed drug eruption was described by Shelley and Shelley (1987). In this variant, which is most common following the use of pseudoephedrine, lesions resolve spontaneously without evidence of postinflammatory pigmentation.

A careful history of previous drug exposures and skin lesions is integral in identification of the causative drug.

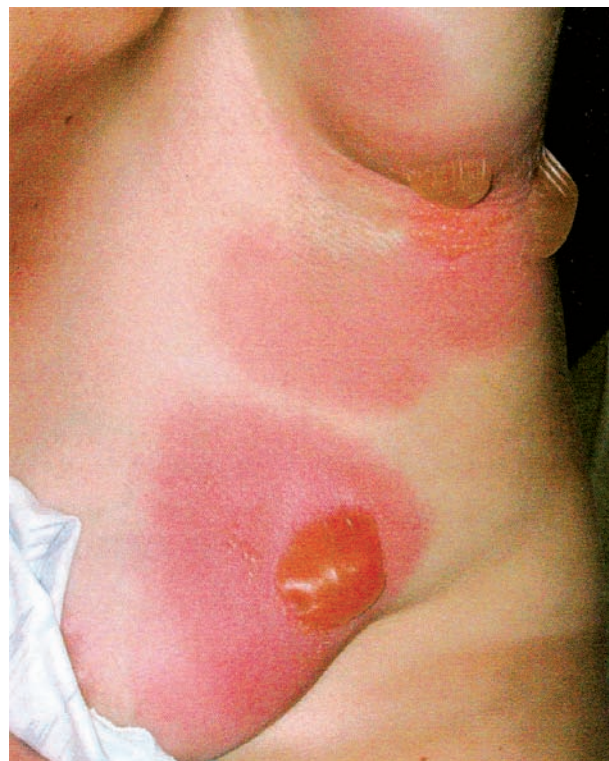

FIG. 3. Bullous fixed drug eruption due to pseudoephedrine. The patient presented with multiple oval erythematous patches following the use of allergy sinus medication containing pseudoephedrine. The patient had two previous episodes from different sympathomimetic medications. Several of the larger patches contained intact flaccid bullae. Bullae formation is uncommon in fixed drug eruption and may be confused with other severe blistering drug reactions, including SJS and TEN.

Provocation testing with oral rechallenge of smaller doses of the suspected agent is the best method to determine with certainty the source of a fixed drug eruption. In cases of bullous or disseminated fixed drug eruption, however, oral challenge may be potentially dangerous. Patch tests, scratch tests, and intracutaneous testing may be helpful if positive, but are less reliable means of testing. When possible, patch testing should be performed at the site of previous eruption in conjunction with a vehicle to aid in drug absorption (Lisi and Stingeni, 1993).

*D. Erythema Multiforme/Stevens-Johnson Syndrome/  
Toxic Epidermal Necrolysis*

The spectrum of severe cutaneous reactions, EM, SJS, and TEN, are the most feared of the CDRs. TEN occurs exclusively as a result of drug exposure and mortality reaches nearly 30%. An epidemiologic survey in France from 1981 to 1985 of private dermatologists, hospital dermatology, burn, intensive care, and infectious disease units estimated the prevalence of TEN to be 1.5 cases per million per year (Roujeau, 1987).

The prototypical lesion of EM is a targetoid dusky erythematous patch, found predominantly on the extremities, although as the name implies, many different morphologies may be observed. EM minor is attributable nearly exclusively to herpetic or mycoplasma infection, whereas EM major, considered by some to be synonymous with SJS, involves the mucous membranes and is associated with drug exposure in approximately 50% of cases. In SJS, bullae form on an erythematous base and confluent areas of skin detachment may be present (Fig. 4). In contrast to EM minor, initial lesions of SJS tend to occur on the face and trunk and are associated with a "burning" sensation or pain, an ominous sign of an impending severe reaction. At least two mucosal sites are involved with SJS. TEN is the most severe form in this reaction spectrum, occurring when large areas of skin sloughing affect greater than 30% of the total body surface area.

Constitutional symptoms are more common with TEN, but both TEN and SJS patients may present with fever that precedes the mucocutaneous eruption by 1 to 3 days (Roujeau and Stern, 1994). The mucocutaneous findings of both SJS and TEN progress rapidly over hours to days. Lesions of the gastrointestinal and respiratory tract are not uncommon in these reactions, the latter of which may be a significant source of mortality. Conjunctival involvement may result in synechiae, per-

sistent photophobia, visual impairment, or complete blindness (Roujeau and Stern, 1994).

Skin biopsy may be helpful in excluding other bullous dermatoses. Some authors believe that EM due to non-drug causes should be considered a distinct entity from more severe drug-induced SJS and TEN. EM is characterized by a dense dermal inflammatory cell infiltrate and keratinocyte necrosis. In contrast, TEN shows complete epidermal necrosis and a sparse mononuclear cell infiltrate (Paquet and Piérard, 1997).

If a severe cutaneous reaction is suspected, immediate withdrawal of all potential offending agents is the most effective mode of therapy. Patients with extensive involvement should be cared for as a "burn patient" with fluid resuscitation, infection control measures, and nutritional support in a hospital burn-unit setting.

Antibiotics, particularly sulfonamides and penicillins, are traditionally implicated in many cases of severe drug reactions, but Roujeau's (1987) survey of drug eruptions in France from 1981 to 1985 found that NSAIDs had emerged as the more common cause of TEN. This was attributed in part to the availability of several new NSAIDs after 1980 (Roujeau, 1987). A list of the agents most frequently associated with SJS and TEN is given in Table 1 (Chan et al., 1990; Roujeau et al., 1990, 1995).

Rechallenge with an offending agent may result in a more severe phenotype and should not be performed following a severe drug reaction (Roujeau and Stern, 1994). Although the onset of severe cutaneous eruptions is typically one to three weeks after initiation of therapy, it may be significantly shorter upon rechallenge. Patch testing has been advocated in cases of severe CDR involving multiple candidate drugs and in which the patient may require future treatment with one of the possible agents (Gebhardt and Wollina, 1997). Difficulties arise in terms of finding an appropriate preparation of the drug suitable for patch testing and the potential risk of eliciting a severe adverse reaction.

### III. Mechanisms of Cutaneous Drug Reactions

Being among the most frequent adverse reactions to drugs, cutaneous reactions represent common ground when it comes to patients being labeled as "allergic" to an offending (real or presumed) agent. This label, however, fails to differentiate between the many mechanisms by which drugs can elicit adverse reactions manifested in the skin; some of which may not be immune-mediated. An understanding of the various mechanisms of CDRs is essential for the identification of predisposing factors, likelihood of cross-reactivity, expected time course, and advisability of subsequent or continued therapy with the offending or related agents.

The proper terminology for reactions to drugs that are believed to be immune-mediated is an area of debate. Immunologists frequently define the term allergy as "disease mediated by the immune system to an other-

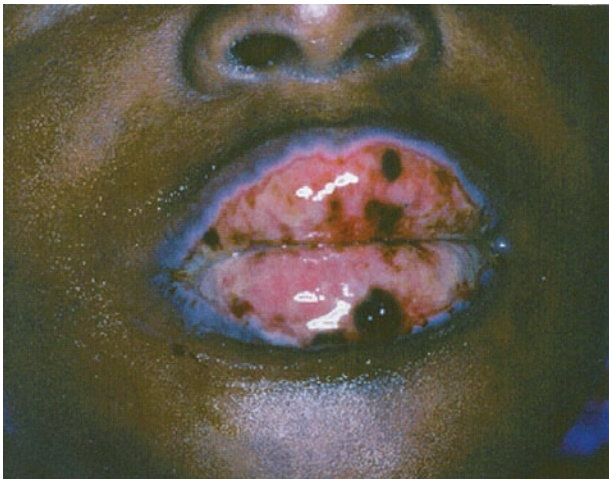

FIG. 4. Erythema multiforme major/Stevens-Johnson syndrome. This HIV-infected patient developed desquamation of the oral mucosa following administration of trimethoprim-sulfamethoxazole.

wise innocuous agent". Although this definition may well describe the reaction to foodstuffs and environmental allergens, strict adherence to this definition would exclude drugs since they are anything but innocuous. Some object to the use of the term hypersensitivity for such reactions, because it "invites confusion with other kinds of adverse reactions" (Pratt, 1990). Moreover, a patient who exhibits a pharmacologic response to a drug (that is not rooted in an immune response) at a dose considerably lower than that needed to elicit the same response in the average individual, could properly be described as "hypersensitive" to that drug. Recognizing the ambiguity in the terminology frequently used for such reactions, it is probably best to refer to these reactions in general as *idiosyncratic* drug reactions. This classification is particularly helpful because it describes the unexpected and low incidence of these reactions while recognizing that the mechanism of many such reactions are still poorly understood. However, even this term has limited usefulness. For example, can a reaction that occurs in over 40% of a patient population (such as a rash during sulfonamide treatment in patients with AIDS) and is, therefore, not of low incidence, be accurately called idiosyncratic? Hence, defining reactions based upon mechanisms, where known, is a preferable means of classification. Where evidence of an immune-mediated response does exist, classification of reactions as immediate-type immune-mediated or delayed-type immune-mediated drug reactions will be used in this review.

#### A. Immediate-Type Immune-Mediated Drug Reactions

Immediate-type immune-mediated (also referred to as Type I hypersensitivity) reactions have been widely studied and are mediated by IgE. As such, a *sensitizing* exposure to the offending drug must occur prior to *elicitation* of an IgE response. The sensitizing period may occur during a previous administration of the drug or during the initial course of treatment, followed by elicitation as the drug regimen is continued. It is also important to recognize that sensitization may occur via environmental exposure to agents with antigenic determinants similar to those expressed by a drug or drug-protein complex, which may subsequently elicit an immediate-type immune-mediated reaction upon *initial* exposure to the drug. For example, Baldo and Pharm (1994) have demonstrated that sera in one patient with an anaphylactic reaction to a commercial hair treatment contained IgE, which reacted with neuromuscular blocking agents; a reaction that was inhibited by a quaternary ammonium derivative in the hair treatment preparation. Moreover, this component in the commercial preparation was able to inhibit the binding of *d*-tubocurarine to IgE in the sera of three patients who previously experienced life-threatening reactions to a neuromuscular blocker. Thus, failure to identify prior exposure to a drug does not rule out the possibility of an immediate-

type immune-mediated drug reaction upon initiation of therapy.

Unlike most antibody isotypes, IgE is primarily located in tissues bound to mast cells. Immediate-type immune-mediated reactions are elicited when an allergen cross-links with preformed IgE on mast cells. This binding results in the degranulation of mast cells, resulting in the release of a variety of toxic mediators (histamine, heparin), cytokines [interleukin (IL)-3, IL-4, IL-5, tumor necrosis factor  $\alpha$  (TNF $\alpha$ )], lipid mediators (leukotrienes C4 and D4, platelet-activating factor), and enzymes (trypase, chymase, cathepsin G, carboxypeptidase) (Janeway et al., 1999). The descriptor, immediate-type immune-mediated reaction, denotes the rapidity with which the reaction develops, generally occurring in two phases. The immediate phase can occur within seconds of drug exposure and results from the rapid release of toxic mediators, especially histamine, causing an increase in vascular permeability and contraction of smooth muscle. When provoked via systemic administration, this results in a disseminated reaction known as urticaria (or hives), which is manifested as large, red and itchy welts on the skin. When precipitated by local intradermal injection (as occurs in allergy testing or an insect sting), the result is the classic wheal-and-flare reaction. A late-phase reaction generally follows that is mediated by the expression of cytokines and chemokines, resulting in recruitment of a variety of inflammatory cells, including eosinophils. This recruitment causes a more widespread edematous reaction. Persistence of antigen can result in a chronic inflammatory condition.

An immediate-type immune-mediated reaction may be associated with disseminated mast cell activation, resulting in marked changes in vascular permeability, epiglottal swelling, constriction of airways, and vascular collapse. This syndrome is known as *anaphylactic shock* and represents a life-threatening phenomenon, potentially resulting in death within minutes.

The signals that initiate mast cell degranulation appear to necessitate the formation of antigen-antibody complexes that result in the cross-linking of adjacent IgE molecules (Baldo and Pharm, 1994; Janeway et al., 1999). This would appear to exclude small molecules, such as drugs, from eliciting such reactions. Because clinical experience substantiates that small molecules do in fact elicit such reactions, it was postulated that linkage of the drug with an endogenous protein was necessary to create the molecular size necessary for such cross-linking. Although quaternary ammonium compounds may represent an exception, numerous studies have demonstrated the importance of hapten-protein conjugate formation in the provocation of immediate-type immune-mediated drug toxicity (Didier et al., 1987).

The basis for our current understanding of the role of hapten-protein conjugates in immune-mediated reac-

tions to small molecules is derived largely from studies on the mechanism of these reactions induced by penicillin (Ahlstedt and Kristofferson, 1982). Penicillin is a reactive compound that readily decomposes to form several compounds that have been demonstrated to covalently bind to proteins and represent the primary antigenic determinants of penicillin (Fig. 5). Of the penicillin molecules that covalently bind to protein under physiological conditions, 95% form penicilloyl groups (Baldo, 1999). This forms the basis for the designation of this as a "major" antigenic determinant, rather than inherent immunogenicity. Sera from subjects who have experienced an immediate-type reaction to penicillin exhibit heterogeneity in the IgE antibody response to antigenic determinants, supporting the presence of multiple antigenic determinants (Harle and Baldo, 1990). Conjugation most often occurs via amide linkage to the side chain  $\epsilon$ -amino group on lysine residues, but may also occur via other residues (e.g., tyrosine).

Differences among penicillin derivatives are based in the side chain, often resulting in differences in reactivity. Antigenic recognition of the common  $\beta$ -lactam ring or thiazolidine rings by antibodies in a patient is indicative of a high degree of cross-reactivity among the various penicillin derivatives. In contrast, side chain group recognition will result in considerably less cross-reactivity (Fig. 6), meaning that those derivatives with dissimilar side chains may not evoke an immune response in a patient with a history of immediate-type immune-mediated reaction toward one of the penicillins (Baldo et al., 1995; Baldo, 1999).

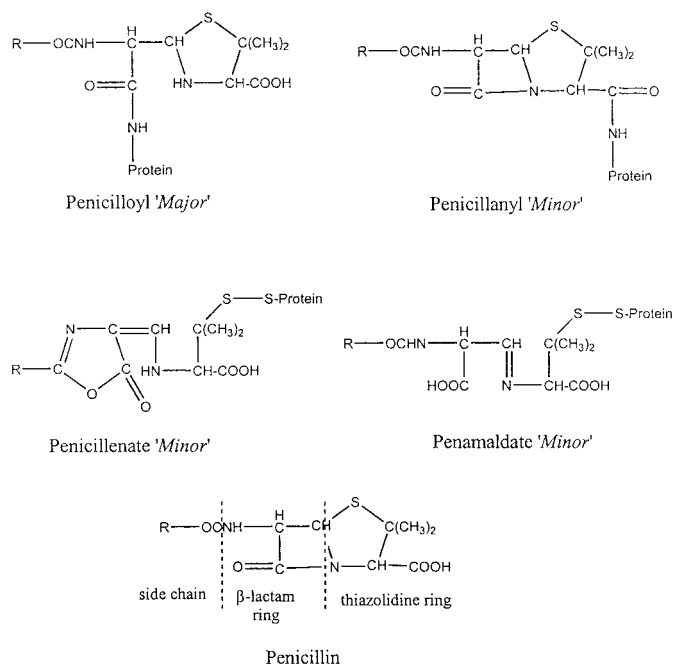


FIG. 5. Structures of the major and minor penicillin antigenic determinants with identified points of attachment to carrier protein. Examples of R groups are illustrated in Fig. 6. Adapted from Baldo and Pharm (1994) with permission.

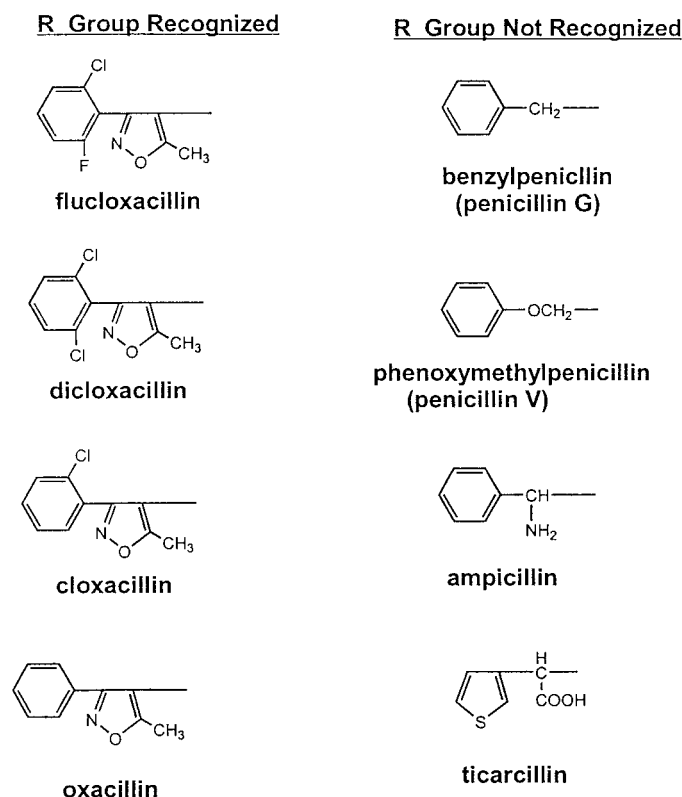


FIG. 6. Specific antigenic recognition of methyl-phenyl-isoxazolyl side chain determinants on penicillin by IgE in the sera of a patient who exhibited a reaction to flucloxacillin. Redrawn from Baldo et al. (1995) with permission.

### B. Delayed-Type Immune-Mediated Drug Reactions

The clinical course of many CDRs suggests they are delayed-type immune-mediated drug reactions. Growing evidence indicates that T-cell recognition of drugs is a critical step in the generation of these responses (Weltzien et al., 1996; Coleman and Blanca, 1998; Pichler et al., 1998). T-cells possess clonally distributed receptors (TCR) that recognize antigen on the cell surface when presented by products of the major histocompatibility complex (MHC) genes. This cell surface-dependent recognition is referred to as MHC-restricted antigen recognition. CD4<sup>+</sup> T-helper cells recognize antigen presented by MHC Class II, while those antigens presented by MHC Class I are recognized by CD8<sup>+</sup> cytotoxic T-cells.

Evidence for the role of T-cell activation in CDR derives from numerous studies wherein drug-specific T-cell clones have been derived from the peripheral blood of patients with a history of such reactions to amoxicillin, carbamazepine, lidocaine, phenytoin, or SMX (Mauri-Hellweg et al., 1995; Zanni et al., 1996, 1997; Horton et al., 1998). Most of these drug-specific clones express the  $\alpha\beta$  TCR type, although some clones have been identified that express the  $\gamma\delta$  TCR type (Zanni et al., 1997; von Greyerz et al., 1999). Hertl et al. (1995) have demonstrated that dermal T-cells isolated from skin lesions in a patient with severe blistering exanthem caused by trimethoprim-SMX (TMP-SMX) proliferated

in response to SMX (but not TMP) in the presence of autologous mononuclear cells (used as antigen-presenting cells, APC). Immunohistochemical studies have demonstrated the infiltration of CD4<sup>+</sup> and CD8<sup>+</sup> T-cells in drug-induced TEN (Leyva et al., 2000).

Because most drugs are of low molecular weight, their recognition as antigens is believed to necessitate the haptentation discussed previously. Few agents are chemically reactive and able to covalently bind with proteins and, thereby, directly act as haptens. Most drugs that evoke a delayed-type immune-mediated reaction are believed to undergo bioactivation to generate haptens that are recognized by sensitized lymphocytes (Merk et al., 1997). Hence, many investigations have focused on the role of bioactivation of causative agents to reactive metabolites, which may in turn bind to critical macromolecules and initiate the immune cascade that eventually presents as a delayed-type immune-mediated CDR. Numerous studies have demonstrated that several sulfonamides, as well as the sulfone dapsone, can undergo biotransformation to form reactive *N*-hydroxylamine metabolites (Rieder et al., 1988; Coleman et al., 1989; Cribb and Spielberg, 1990a,b, 1992; Cribb et al., 1996b). These studies indicate that the ability to detoxify these reactive metabolites may be an important determinant in the development of CDR. Interestingly, several studies have suggested that the *in vitro* cytotoxicity of these hydroxylamines toward peripheral blood mononuclear cells can predict predisposition to delayed-type immune-mediated reactions toward sulfonamides (Shear et al., 1986; Rieder et al., 1989; Carr et al., 1993b; Wolkenstein et al., 1995b).

The anticonvulsants phenytoin and carbamazepine (which are also among the highest CDR-producing drugs) can also be metabolized by liver microsomes to reactive metabolites that are cytotoxic and exhibit covalent binding to macromolecules (Spielberg et al., 1981b; Roy and Snodgrass, 1990; Pirmohamed et al., 1992; Furst and Uetrecht, 1993; Castren et al., 1996). It has also been demonstrated that lymphocytes isolated from patients with a history of a CDR to phenytoin or carbamazepine incubated with parent drug and liver microsomes exhibit a higher cell death than lymphocytes from patients without a history of such a reaction (Shear and Spielberg, 1988; Wolkenstein et al., 1995b). This suggests that a defect in detoxifying enzymes may be an important predisposing factor for the development of CDRs to anticonvulsants.

One question that arises from these observations is, how can reactive metabolites generated in the liver survive transit to the sites where delayed-type hypersensitivity is manifested (most commonly, the skin)? It has been proposed that circulating immune cells may catalyze the bioactivation of these agents (Uetrecht, 1992; Furst and Uetrecht, 1993; Uetrecht et al., 1993). Indeed, activated monocytes and neutrophils have been shown to convert numerous CDR-evoking drugs to reactive metabolites

(Furst and Uetrecht, 1993, 1995; Uetrecht et al., 1993; Lai et al., 1999). Using aniline as a model compound, Wulferink et al. (2001) have demonstrated that prohap- tens incubated with white bone marrow cells form neoantigens that are recognized by T-cells. To date, however, there is no explanation for why reactive metabolites generated in circulating immune cells would display the type of specificity in reaction site that is reported with drugs associated with these reactions. We have, therefore, developed a working hypothesis wherein events occurring in the cutaneous environment are the primary factors initiating these reactions (Reilly et al., 2000).

As shown in Fig. 7, it is proposed that bioactivation occurs in or near keratinocytes. Wolkenstein et al. (1998) have demonstrated that isoforms of cytochrome P450 that form the reactive metabolite of carbamazepine are present in the skin. In addition, we have demonstrated that cultured human keratinocytes are able to bioactivate SMX and dapsone to their respective hydroxylamine metabolites (Reilly et al., 2000). Moreover, the well known photosensitivity of patients receiving numerous drugs that evoke a delayed-type immune-mediated CDR suggests these drugs do reach the cutaneous level after systemic administration (Selvaag, 1997; Vassileva et al., 1998; Epstein, 1999).

Long recognized for its importance in the structural integrity of the skin, the epidermal keratinocyte is a key cell in the initiation and propagation of cutaneous immune reactions (Stoof et al., 1994; Nickoloff et al., 1995). Keratinocyte-derived cytokines provide essential signals for the migration of Langerhans cells, which are believed to be the predominant APC in the skin (Cumberbatch et al., 1994, 1997a,b, 1999; Cumberbatch and Kimber, 1995). Modulation of the expression of these keratinocyte-derived cytokines may, therefore, impact antigen presentation and, ultimately, T-cell activation.

As shown in Fig. 7, we hypothesize three avenues that may be important in the initiation of CDR after exposure to reactive metabolites: 1) a direct cytotoxic effect, 2) stimulation of danger signal(s) expression, and/or 3) stimulation of adhesion/costimulatory molecule expression. Importantly, we have demonstrated that incubation of SMX, dapsone, or their respective hydroxylamine metabolites, with normal human keratinocytes results in the formation of drug/metabolite-protein adducts, even in the absence of cytotoxicity (Reilly et al., 2000; W. L. Wurster and C. K. Svensson, unpublished observations). Thus, antigen presentation may occur as the result of cytotoxicity or in its absence. Since keratinocytes have been shown to express human leukocyte antigen (HLA-DR) at inflammatory sites (Barbaud et al., 1997), it is possible that these cells may serve as APC in situations that predispose subjects to CDRs. Moreover, keratinocytes have been demonstrated to express accessory molecules that serve as important "second signals" in the activation of T-cells (Nickoloff et al., 1993, 1995).



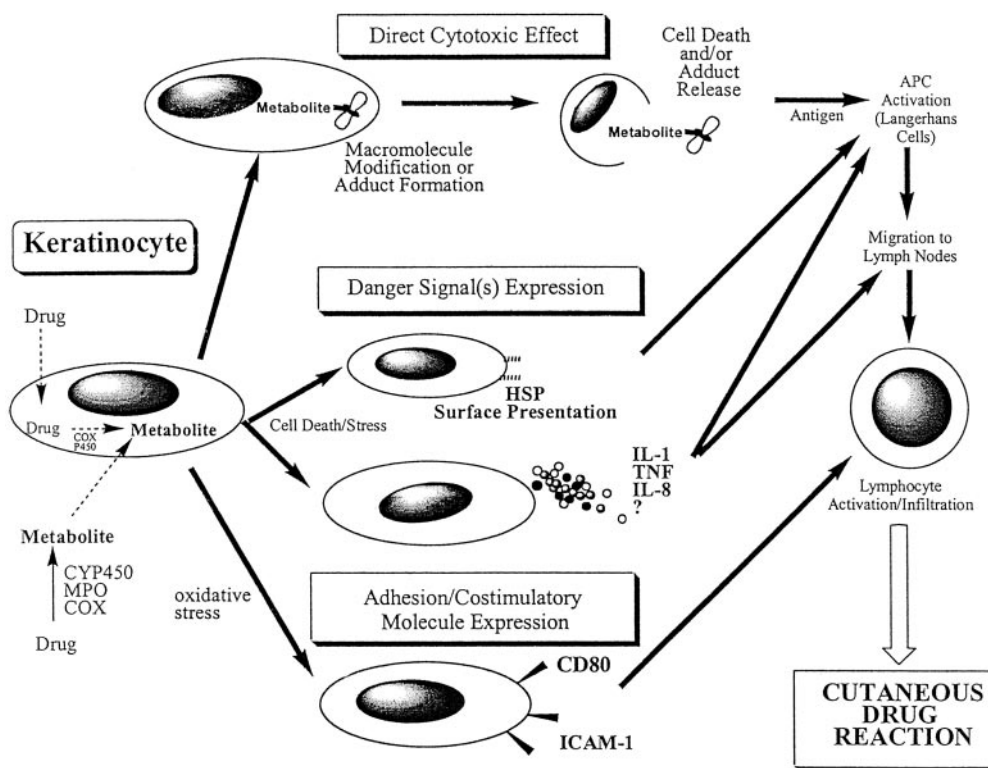


FIG. 7. Working hypothesis for the mechanism of cutaneous drug reactions. Adapted from Reilly et al. (2000) with permission. CD80, B7.1 costimulatory molecule.

Binding of antigen to an antigen-specific receptor (i.e., TCR) is, in itself, insufficient to evoke an immune response. Costimulatory signals are necessary to trigger clonal activation and expansion of T-cells, and in their absence, clonal inhibition and elimination occur (see Figs. 8 and 9) (Goodnow, 1996; van Parijs and Abbas, 1998). The prevailing view has long been that exogenous signals are essential in the control of this response, but growing evidence indicates that endogenous signals may

be of equal or greater importance in some immune responses (Ibrahim et al., 1995; Matzinger and Fuchs, 1996; Matzinger, 1998). It has been suggested that damaged or stressed cells release “danger (alarm) signals” that activate local APC, resulting in antigen uptake, migration to the draining lymph nodes, and up-regulation of further stimulatory signals important for the activation of T-cells. Indeed, resident dendritic cells may serve as sentinel cells, responding to signals of cell stress or “unnatural” cell death. The detection of these events may be the primary determinant of the immune system’s response to foreign elements. For example, numerous experiments have demonstrated that resident Langerhans cells in the skin acquire dendritic cell properties when exposed to cytokines such as granulocyte-macrophage-colony stimulating factor, TNF- $\alpha$  and IL-1 $\beta$  (Lappin et al., 1996; Kimber et al., 1998). Injured cells (e.g., keratinocytes) may serve as the primary source for these cytokines. It has recently been suggested that altered surface expression of heat shock proteins (HSP) may serve as a primary signal of cell stress in response to sublethal cell injury (Ibrahim et al., 1995; Matzinger and Fuchs, 1996; Matzinger, 1998; Todryk et al., 2000). It has also been suggested that  $\gamma\delta$  T-cells may serve a critical function in the surveillance for damaged cells, which are subsequently eliminated (Boismenu and Havarán, 1997, 1998; Salerno and Dieli, 1998). Similar signals have been hypothesized to play a role in the response to this cell type, especially HSP. Interestingly, it

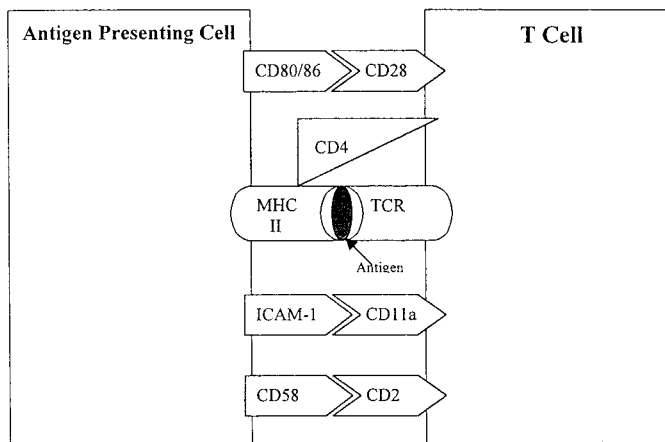


FIG. 8. Antigen-presenting cell and T-cell interaction. Langerhans’ cells in the skin become potent APC due to the expression of critical molecules such as class II MHC. They also increase their expression of accessory molecules, such as ICAM-1, CD58, and CD80/86. These accessory molecules allow T-cells to adhere to APC and also deliver “second signals” to T-cells to amplify the APC-derived “first signal” (i.e., MHC II-hapten complex). Adapted from Gaspari (1993) with permission.

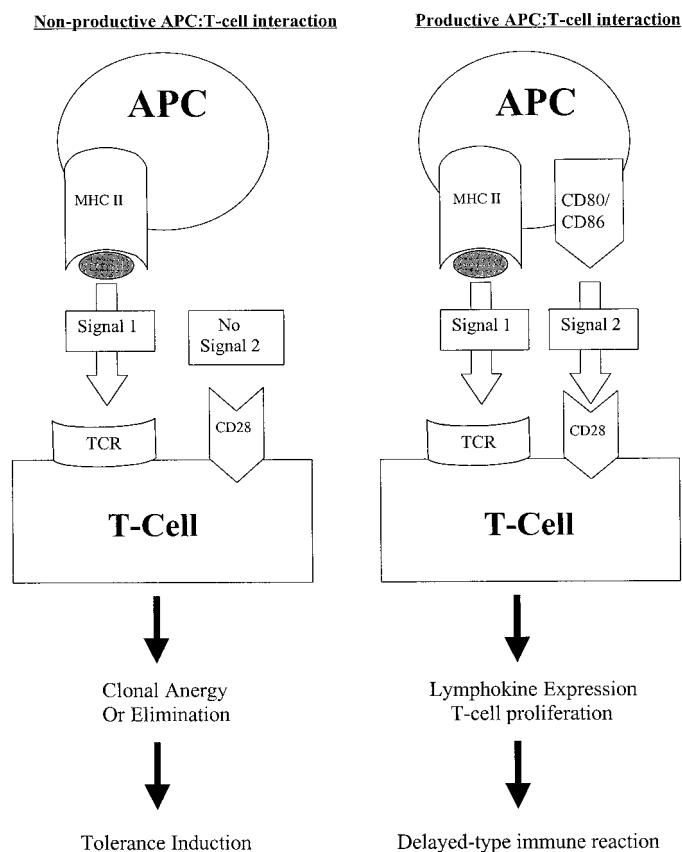


FIG. 9. Potential consequences of antigen presentation by APC. T-cell activation by APC, such as Langerhans' cells in the skin, requires two signals. Antigen presentation on MHC II molecules (which represents signal 1) in the absence of signal 2 results in clonal anergy and tolerance. Presentation of antigen together with signal 2 results in T-cell activation and proliferation, the liberation of lymphokines, and initiation of events that manifest as a CDR. Endogenous signals (i.e., "danger" signals) from stressed cells may induce the expression of CD80/86 on APC, thereby providing the second signal for T-cell activation. Gray oval represents antigen. Adapted from Gaspari (1993) with permission.

has been reported that both HSP27 and HSP70 were expressed in the epidermis during severe drug eruption (Nishioka et al., 1999). Thus, dysregulated cell death/stress resulting from exposure to reactive metabolites may result in important signals that stimulate APC activation, including heat shock proteins and cytokines that have been demonstrated to be important in Langerhans' cell migration.

T-cell activation by APC necessitates two signals (Fig. 9). The interaction of the antigen presented on major histocompatibility complex and its cognate TCR provides the first signal (Martin and Weltzien, 1994). The second signal arises from the interaction between a costimulatory molecule and its specific receptor on the T-cell surface. Langerhans' cells (the primary APC in the skin) express numerous costimulatory molecules, including CD80 (B7.1) and CD86 (B7.2) (Gaspari, 1993; Nickoloff and Turka, 1994). Importantly, we have recently demonstrated that CD80 may be expressed in normal human keratinocytes exposed to contact irritants and allergens (Wakem et al., 2000). This suggests

the possibility that exposure of keratinocytes to reactive metabolites may induce expression of CD80 and allow these cells to provide the critical second signal for T-cell activation.

Intercellular adhesion molecule-1 (ICAM-1; also known as CD54) plays an important role in cell-mediated immune responses, including drawing cells to the local environment (Boyd et al., 1988). Common sensitizing agents, such as nickel, *p*-phenylenediamine, and urushiol (the antigen in poison ivy) have been shown to induce the expression of ICAM-1 in cultured human keratinocytes (Griffiths and Nickoloff, 1989; Picardo et al., 1992; Gueniche et al., 1994a,b). Other investigators have provided evidence that this induction of ICAM-1 is secondary to oxidative stress (Little et al., 1998; Camins et al., 1999). Induction of ICAM-1 upon exposure to reactive metabolites, which may in turn induce oxidative stress, might be expected to enhance lymphocyte infiltration, making it an important step in initiation of these CDRs.

It should be noted that a new model for recognition of small molecules by *activated* T-cells has recently been proposed that is metabolism-independent and does not require antigen processing (Horton et al., 1998; Pichler et al., 1998; Zanni et al., 1998). It is postulated that drugs may complex with preformed MHC-peptide complexes already expressed on the cell surface. Incubation of SMX or amoxicillin with glutaraldehyde-fixed APC (which are unable to process antigen but can present preprocessed antigen) results in the activation of drug-specific T-cell clones. Because a washing step negated the activation, it appears that the binding occurs in a noncovalent fashion (Zanni et al., 1998). Although these preliminary observations suggest an alternative pathway for T-cell activation, the demonstration that metabolism and processing are not essential does not mean they are not involved in the reactions. It remains to be determined whether or not incubation with reactive metabolites of the compounds would provoke a more profound activation than that seen via incubation with the parent drug. Moreover, the vast majority of evidence indicates that such reactions do not occur in the absence of reactive metabolite formation (Utrecht, 1999). In addition, if these reactions are mediated by nonreactive SMX interacting with preformed MHC-peptide complexes, it is difficult to understand why more patients receiving the drug do not manifest CDR. Whether or not a similar process can mediate *sensitization* remains to be explored.

### C. Photosensitivity Reactions

Photosensitivity is a general term used to describe individuals that exhibit an increased incidence of erythema upon exposure to ultraviolet radiation. This may be manifested as an inflammatory reaction upon exposure to normally harmless levels of electromagnetic radiation or an exaggerated response to inflammation-

inducing levels. Although photosensitivity can be observed upon irradiation with visible light (e.g., porphyrins and some dyes), most of these reactions occur upon exposure to radiation in the UV range; ultraviolet A (UVA, 320 to 400 nm) or ultraviolet B (UVB, 290 to 320 nm). Because the ozone layer blocks ultraviolet C (200 to 290 nm) radiation, chromophores absorbing in this range do not pose a hazard for subjects exposed to natural light. The majority of drugs that have been reported to be associated with photosensitivity absorb in the UVA region.

The initial step in any photosensitivity reaction is the absorption of a photon. Thus, only those agents with an absorption spectrum in the range of sunlight are associated with photosensitivity. The two primary forms of drug-induced photosensitivity are phototoxicity and photoallergy. Some drugs, such as several of the fluoroquinolones, may induce photosensitivity by both mechanisms (Tokura, 1998).

**1. Phototoxicity.** Phototoxic reactions are those in which the photoactivated drug or photodegradation products cause direct cellular damage. The reaction is dependent upon the amount of the compound, level of activating radiation, and the quantity of other chromophores in the skin (e.g., epidermal keratins, melanin, etc.) (Shimoda et al., 2000). For example, using data from the French Pharmacovigilance System, Pierfitte et al. (2000) found a strong correlation between UV irradiation and the reporting rate of phototoxic reactions to the fluoroquinolone, sparfloxacin. In fact, this is perhaps the clearest demonstration of the relationship between an environmental factor and an ADR. Under the right conditions, all individuals exposed to the drug and sunlight in adequate levels would be expected to manifest photosensitivity.

The general mechanism of drug-induced phototoxicity is outlined in Fig. 10. Absorption of UV light produces an excited state drug or metabolite, which may in turn follow one of two pathways that ultimately lead to pho-

tosensitization (Moore, 1998). The first pathway proceeds through the generation of a free radical. Evidence for free radical photoproducts have been demonstrated for several compounds, including naproxen and sulfamethoxazole, by electron paramagnetic resonance (EPR) or photopolymerization of acrylamide (Moore and Chappuis, 1988; Zhou and Moore, 1997). Photoactivated SMX is able to reduce cytochrome *c* in both deoxygenated and oxygenated conditions, indicating the ability for direct electron transfer from the free radical. Thus, following free radical formation, the photoproduct may participate in direct electron transfer or covalently bind to key cellular components. Photoactivation of drugs that yield adducts with macromolecules have been demonstrated in vitro for several NSAIDs and fluoroquinolones (Tokura, 1998; Moser et al., 2000a,b; Ohshima et al., 2000).

A second pathway by which a phototoxic compound can lead to photosensitization is through the generation of singlet oxygen, which in turn results in the oxidation of biomolecules, damaging critical cellular components and initiating the release of erythrogenic mediators. The formation of singlet oxygen after photoactivation has been demonstrated in vitro with SMX and several NSAIDs (Moore and Chappuis, 1988; Moore et al., 1990; Zhou and Moore, 1997). The signal that activates the release of erythrogenic mediators has not been identified, although activation of protein kinase C and tyrosine kinase have been implicated (Shimoda and Kato, 1998).

**2. Photoallergy.** Drug-induced photoallergy exhibits the characteristics of a delayed-type immune-mediated reaction. These reactions only develop in sensitized individuals and appear to be cell-mediated. The earliest evidence of an immune-mediated photosensitivity pathway arose from studies with 3,3',4',5-tetrachlorosalicylanilide (TCSA), an allergic contact photosensitizing agent (Kochevar and Harber, 1977; Takigawa and Miyachi, 1982; Tokura et al., 1991). With exposure to UVA, TCSA covalently couples to isolated protein and cells (Kochevar and Harber, 1977; Tokura et al., 1991). T-cell-mediated responses to TCSA-haptenated epidermal cells have been demonstrated in vivo in the mouse.

The fluoroquinolone antimicrobial agents exemplify a class of systemically administered compounds that appear to exhibit predominantly immune-mediated photosensitivity (although sparfloxacin appears to be primarily phototoxic) (Tokura, 1998). Exposure of a solution of an 8-fluorene-substituted fluoroquinolone and albumin to UVA gives rise to a fluoroquinolone-albumin adduct (Tokura et al., 1996; Marutani et al., 1998). Moreover, mice receiving an intraperitoneal injection of a fluoroquinolone and exposed to UVA exhibit epidermal cells with fluoroquinolone-adducts (Tokura, 1998). This demonstrates that systemically administered drug not only reaches the skin but does so in quantities adequate to undergo photoactivation and production of detectable levels of drug-protein adduct. Using the murine ear

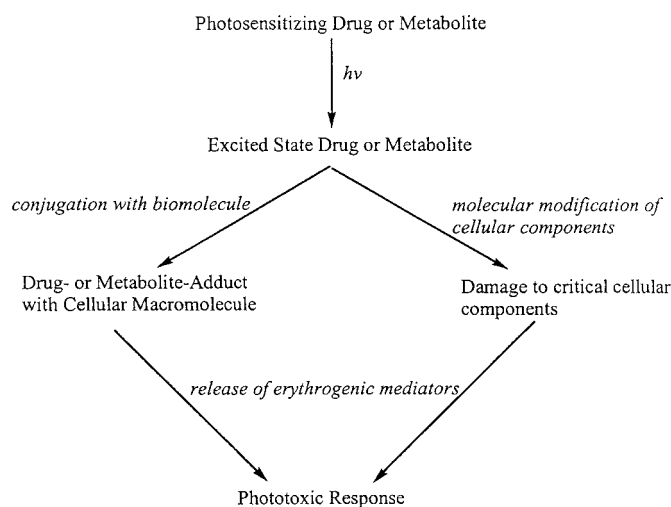


FIG. 10. General scheme for the mechanism of phototoxic reactions.

swelling test, Ohshima and associates (2000) have demonstrated a delayed-type immune-mediated response to the fluoroquinolone, fleroxacin. In addition, fleroxacin photomodification of Langerhans' cells could be demonstrated in these animals. Further work by these investigators has demonstrated the presence of circulating sensitized T-cells that react to fluoroquinolone-photo-modified cells in patients with a history of photosensitivity to several fluoroquinolones (Tokura et al., 1999).

#### D. Autoimmune Syndromes

Numerous drug-induced autoimmune diseases are accompanied by cutaneous manifestations. Among these are pemphigus-like skin reactions. A common feature of both idiopathic and drug-induced pemphigus is autoantibodies against one or more keratinocyte cell-surface molecules, including desmoglein I (Koulu et al., 1984; Amagai et al., 1991; Kuechle et al., 1994a). Unlike the case with idiopathic pemphigus, however, the severity of the drug-induced form does not appear to correlate with the level of circulating autoantibodies (O'Loughlin et al., 1978; Kuechle et al., 1994a). The majority of drugs that induce pemphigus-like skin reactions are sulfhydryl-containing compounds, such as penicillamine and captopril. These agents are capable of forming disulfide-linkages to sulfhydryl-containing cysteine residues on a variety of peptides. This ability, however, does not by itself explain the production of autoantibodies. For example, Coleman and associates found that although injection of D-penicillamine resulted in the formation of plasma protein conjugates *in vivo*, no detectable antibody response was produced in rats; while a conjugate of the drug with keyhole limpet hemocyanin readily induced an immune response (Foster et al., 1987; Coleman et al., 1988). Moreover, drug-induced pemphigus has also been reported with the angiotensin-converting enzyme inhibitor enalapril, which is structurally similar to captopril, but lacks the sulfhydryl moiety believed to play a role in these reactions (see Fig. 11) (Kuechle et al., 1994a). A direct effect of drugs on keratinocytes cannot be ruled out as a possible mechanism for these reactions.

Linear IgA bullous dermatosis is another autoimmune disease that may be associated with drug ingestion. This blistering disorder of the subepidermal region is characterized by the linear deposition of IgA in the basement membrane zone (Kuechle et al., 1994b). Drugs implicated in this disorder include amiodarone, captopril, diclofenac, phenytoin, and, most commonly, vancomycin (Acostamadiedo et al., 1998; Klein and Callen, 2000). Although little is known about the mechanism of this disorder, two potential antigens have been identified; a 97-kDa protein in the lamina lucida and a 285-kDa protein in the lamina lucida and sublamina densa regions (Wojnarowska et al., 1991; Zone et al., 1998). How drug ingestion may expose or provoke an antibody response to critical antigenic determinants on these proteins is unknown. Interestingly, there is evidence that triggering events, such as infection, may be necessary to initiate an immune response in this disorder (Thune et al., 1984; Blickenstaff et al., 1988; Godfrey et al., 1990). Thus, it is possible that drugs do not directly cause this disease, but rather represent one of many possible triggering factors for the idiopathic autoimmune disorder.

#### IV. Role of Viral Infection as a Predisposing Factor for Cutaneous Drug Reactions

One of the most perplexing aspects of CDRs is their highly variable nature. In general, only a small fraction of patients who receive a drug will experience a CDR. In addition, some patients who have exhibited a cutaneous reaction that appears reasonably well linked to the suspected drug receive that agent at a later date without experiencing the same reaction (Bonfanti et al., 2000; Carr et al., 1993a; Shafer et al., 1989). Is this because the suspected drug was not the actual cause of the cutaneous reaction? Or could it be that other mitigating factors were necessary for the reaction and those factors were not present upon subsequent administration of the drug? While many investigators have concentrated on identification of innate predisposing factors in patients exhibiting CDRs (e.g., pharmacogenetics), our growing understanding of the multi-factorial nature of many diseases suggests that the presence of transient phenomenon concurrent with drug administration may be critical in determining whether or not a patient exhibits an ADR (Evans, 1982). One factor that appears to significantly increase the risk of CDR is the presence of a viral infection (Haverkos et al., 1991; Levy, 1997).

Pullen et al. (1967) published a study examining the incidence of drug rashes in 184 patients diagnosed with infectious mononucleosis. Of the 121 patients who received one or more antibiotic, 45% exhibited a skin rash, whereas a rash occurred in only 16% of patients not receiving an antibiotic. Rashes were most frequent among patients receiving ampicillin, where 18 of 19 patients receiving the drug experienced an extensive maculopapular, pruritic rash, often accompanied with

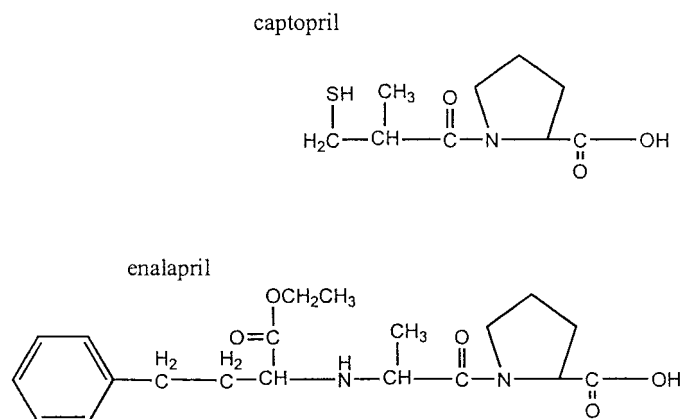


FIG. 11. Structures of captopril and enalapril.

fever. In contrast, only 2 of 17 patients treated with tetracycline exhibited a rash. Patel (1967) reported on the frequency of skin rash in patients with infectious mononucleosis receiving no antibiotic, receiving ampicillin, or receiving other antibiotics (including penicillin and tetracycline). The frequency of skin rash was 9, 100, and 14%, respectively. Similarly, in a series of patients with cytomegalovirus infection, 4 of 5 patients receiving ampicillin exhibited a rash, while only 2 of 23 patients not receiving ampicillin had skin manifestations (Klemola, 1970). This increased sensitivity to ampicillin in the presence of viral infection was shown to be a transient phenomenon in that only 2 of 20 patients experiencing an ampicillin-induced rash during infectious mononucleosis exhibited a recurrent rash when receiving the drug after resolution of the infection (Nazareth et al., 1972).

The incidence of CDRs among patients infected with the human immunodeficiency virus (HIV) is also substantially increased compared with that found in presumed HIV-negative subjects (Coopman and Stern, 1991; Coopman et al., 1993). For example, the Boston Collaborative Drug Surveillance Study found that the incidence of CDR to TMP-SMX in hospitalized patients was 3.3% (Bigby et al., 1986). The frequency of CDRs to TMP-SMX in HIV-infected subjects is reported to be as high as 40 to 60% (Medina et al., 1990; Blum et al., 1992; Pertel and Hirschtick, 1994; Roudier et al., 1994). This increased frequency of CDR does not appear to be secondary to the effects of *Pneumocystis carinii* pneumonia (PCP) infection (the most common indication for the drug in HIV-infected subjects) or the higher doses used in the treatment of PCP. Kovacs et al. (1984) found that CDRs to TMP-SMX in patients being treated for PCP occurred in 10 of 34 HIV-infected patients, but in 0 of 15 patients with other immunosuppressive diseases. In other studies where TMP-SMX has been used in immunosuppressed patients (presumed to be HIV-negative), CDRs have been extremely rare (Winston et al., 1980; Sattler and Remington, 1981). Similarly, the incidence of CDR during treatment with dapsone appears to be higher in HIV-infected subjects (Medina et al., 1990; Blum et al., 1992; Pertel and Hirschtick, 1994). Thiacetazone causes a CDR in 20 to 29% of HIV-infected patients with tuberculosis, but only in 1 to 7% of HIV-negative tuberculosis patients (Nunn et al., 1991; Watkins et al., 1996). Other drugs have been noted to cause an unusually high frequency of CDRs in HIV-infected patients (see Table 2), although whether this represents an "increased" incidence is unclear, since the only indication for the agents is HIV-infection (Ho et al., 1998; Anon, 2000; Centers for Disease Control, 2001).

By what mechanism(s) do viral infections increase the predisposition to the development of CDRs? The working hypothesis that we have previously proposed provides a framework for understanding the potential role of alterations in key immune mediators in predisposing patients to these reactions (Fig. 7) (Reilly et al., 2000). It

TABLE 2  
Incidence of cutaneous drug reactions in HIV-infected subjects<sup>a</sup>

Drugs	Incidence
	%
TMP-SMX	
PCP therapy	27–64
PCP prophylaxis	3–34
Sulfadiazine	10–40
Dapsone	
PCP therapy	17–53
PCP prophylaxis	5–10
Clindamycin	20–30
Thiacetazone	20–27
Nevirapine	20–30
Delavirdine	30
Aminopenicillins <sup>b</sup>	9

<sup>a</sup> Adapted from Carr (1997).

<sup>b</sup> Aminopenicillins: amoxicillin, ampicillin, or amoxicillin-clavulanic acid.

is well known that immune responses in the skin are highly regulated by cytokines and other inflammatory mediators (Kimber et al., 1995; Kimber, 1996; Kimber and Dearman, 1996). Viral and bacterial infections can also result in the release of a variety of cytokines that may up-regulate the expression of key immune-mediating molecules in keratinocytes and Langerhans' cells. For instance, it has also been demonstrated that cyclooxygenase 2 (COX-2) is up-regulated in keratinocytes in an inflammatory response (Lotfin and Eling, 1996; Maldve and Fischer, 1996; Buckman et al., 1998). If COX-2 contributes to the bioactivation of arylamines and other compounds as some studies have suggested (Liu and Levy, 1998; Goebel et al., 1999), an inflammatory response would increase the formation of reactive metabolites in the keratinocyte. Other xenobiotic-metabolizing enzymes have been shown to be either up- or down-regulated in other cells upon exposure to pro-inflammatory cytokines (Morgan, 1997, 2001). In addition, we have shown that glutathione content is a critical factor in determining the susceptibility of keratinocytes to the hydroxylamine metabolite of SMX (Reilly et al., 2000). This observation is significant in that the pro-inflammatory cytokines TNF- $\alpha$  and IL-1 $\beta$  induce a variety of biochemical responses in cells, including decreases in glutathione (Singh et al., 1998). Interestingly, TNF- $\alpha$  is substantially increased in the epidermis of patients with severe CDR (Barbaud et al., 1997). Thus, by their multiple immunological and biochemical effects, viral infections may "prime" the cutaneous environment for a response to agents that result in a CDR.

## V. Cutaneous Drug Reactions Associated with Selected Drugs

### A. Sulfonamides

The incidence of CDR in patients receiving TMP-SMX is higher than for any other drug (Naldi et al., 1999). As the most widely used sulfonamide preparation, it is not surprising that most reported sulfonamide-related CDRs involve this combination. Although it is believed

that the SMX component is responsible for most reactions, CDR in patients receiving trimethoprim monotherapy have also been reported (Das et al., 1988; Nwokolo et al., 1988). As described previously, the frequency of TMP-SMX-associated CDR is substantially increased in HIV-infected subjects (Medina et al., 1990; Blum et al., 1992; Pertel and Hirschtick, 1994; Roudier et al., 1994).

Sulfonamides have been reported to cause a wide range of skin reactions, including erythema multiforme, erythema nodosum, photosensitivity, TEN, and urticarial rashes (Cribb et al., 1996a). The mechanism and time course of these reactions varies considerably. Episodes of urticarial rash, generally not accompanied by fever, can occur within the first 3 days of therapy with a sulfonamide. Although anaphylaxis may not accompany the initial CDR, re-exposure can provoke this life-threatening reaction. These reactions appear to be immediate-type immune-mediated reactions that are associated with the presence of IgE antibodies toward the sulfonamide (Carrington et al., 1987; Harle et al., 1988; Gruchalla and Sullivan, 1991). Binding specificity studies suggest the 5-methyl-3-isoxazolyl group on SMX is a key component in antibody recognition (Harle et al., 1988). In vitro cross-reactivity with a variety of sulfonamides suggests such reactions may occur across a spectrum of sulfonamides in a given patient. The response to skin testing is variable and does not appear to identify a significant portion of patients with a positive history of urticarial CDR to sulfonamides (Leftwich, 1944; Gruchalla and Sullivan, 1991).

Sulfonamides also induce a delayed-type reaction that appears to be immune-mediated. These reactions are generally manifested 7 to 14 days after the initiation of therapy with the sulfonamide and most commonly present as fever, together with a morbilliform or maculopapular, non-urticarial skin rash. Patients may also progress to SJS or TEN. The incidence of these severe cutaneous reactions with sulfonamides is estimated to be between 1:1000 and 1:100,000 (Chan et al., 1990; Roujeau and Stern, 1994). In addition to CDRs, sulfonamides have been associated with a multiorgan syndrome, most frequently involving fever, rash, eosinophilia, and hepatotoxicity, which develops after a week or more of therapy (Dujovne et al., 1967; Berg and Daniel, 1987; Rieder et al., 1989). The incidence of this multiorgan syndrome appears to be less than 0.1% (Cribb et al., 1996a).

The ability to demonstrate drug-specific activated T-cell clones in patients exhibiting these delayed-type reactions supports the contention that they are immune-mediated (Warrington et al., 1983; Kalish et al., 1994; Hertl et al., 1995; Mauri-Hellweg et al., 1995; Schnyder et al., 1997, 1998; von Greyerz et al., 1999). Such clones are, however, at low frequency and not detectable in all patients with these delayed-type reactions.

Numerous lines of evidence suggest the need for bioactivation of the sulfonamide prior to initiation of a CDR. Figure 12 illustrates the proposed bioactivation-dependent mechanism for SMX-induced delayed-type immune-mediated reactions. The first evidence of the importance of metabolism as a predisposing factor for these reactions was provided by Shear et al. (1986), who found that six of six children who experienced serious reactions (CDR plus systemic organ involvement) to a sulfonamide exhibited the slow acetylator phenotype. In contrast, a cohort of control subjects exhibited a frequency of slow acetylators of 56%. Moreover, lymphocytes from these patients exposed in vitro to several sulfonamides plus murine liver microsomes exhibited a higher percentage of cell death than lymphocytes from control subjects (Shear et al., 1986). These data suggest that subjects with a delayed-type immune-mediated reaction to sulfonamides may have a defect that reduces their ability to detoxify reactive sulfonamide metabolites. It also suggests that patients with the slow acetylator phenotype may be at greater risk of such reactions because they are presumed to bioactivate a larger fraction of the administered dose via cytochromes P450. Subsequent studies have confirmed this latter observation in patients experiencing a sulfonamide-induced delayed-type immune-mediated reaction (Rieder et al., 1988; Wolkenstein et al., 1995b). Moreover, it has been demonstrated that humans metabolize SMX to a hydroxylamine metabolite that exerts a cytotoxic effect on peripheral blood mononuclear cells that is more extensive in patients with a history of such reactions (Rieder et al., 1988; Cribb and Spielberg, 1992; van der Ven et

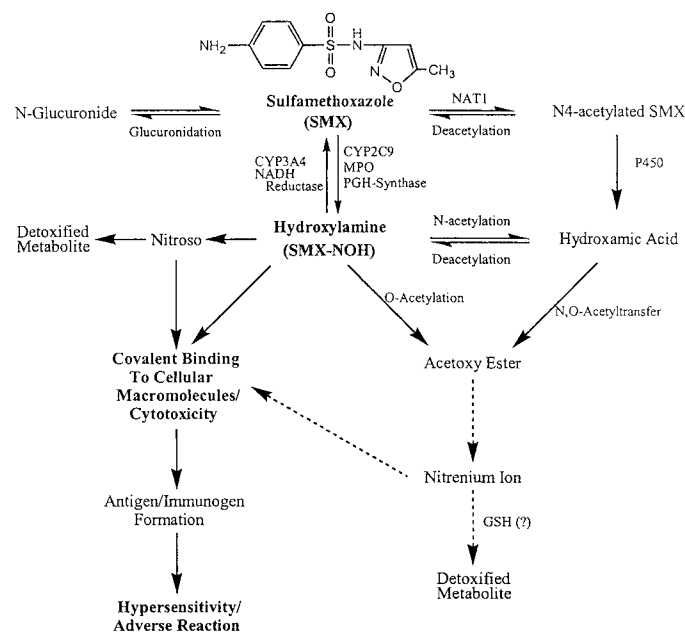


FIG. 12. Proposed "bioactivation-dependent" pathway for sulfamethoxazole-induced delayed-type immune-mediated reactions. MPO, myeloperoxidase; NAT1, *N*-acetyltransferase 1; PGH-synthase, prostaglandin H synthase.

al., 1994). The nature of the detoxification defect remains to be identified, but preliminary studies do not support early suggestions that deficiency in glutathione *S*-transferase is responsible (Riley et al., 1991).

Once formed, the hydroxylamine metabolite of SMX (SMX-NOH) undergoes a series of enzymatic and non-enzymatic reactions that bear significantly on its toxicity (Fig. 13). Evidence suggests that nitroso-SMX may be the proximate toxin responsible for cell death and covalent binding (Cribb et al., 1991, 1996b; Rieder et al., 1995). Acetylation, reaction with GSH, or reduction back to the hydroxylamine have all been shown to reduce the covalent binding of nitroso-SMX in vitro (Cribb et al., 1991, 1996b).

Several studies have confirmed the role of the slow acetylator phenotype or genotype as a predisposing factor in the development of sulfonamide-induced CDRs (Rieder et al., 1991; Wolkenstein et al., 1995a; Zielinska

et al., 1998). These observations are somewhat perplexing, since the slow acetylator phenotype reflects a reduction in *N*-acetyltransferase 2 (NAT2), whereas NAT1 appears to be the primary determinant of SMX acetylation (Cribb et al., 1993). This apparent discrepancy may be explained by the in vitro observations that NAT2 is able to acetylate SMX-NOH, as well as reduce its covalent binding to protein (Nakamura et al., 1995; Cribb et al., 1996b). Thus, NAT2 may play an important role in the detoxification of SMX-NOH formed in vivo.

The ability of reactive metabolites of sulfonamides to bind covalently to proteins in vitro suggests that bioactivation may lead to the formation of metabolite-protein conjugates in vivo. Indeed, it has been reported that some patients receiving SMX or TMP-SMX have detectable SMX-protein conjugates circulating in their sera (Meekins et al., 1994; Gruchalla et al., 1998). However, these drug-protein conjugates have been detected in patients with and those without a history of CDR to SMX, and appear to be present in ~50% of subjects receiving the drug. The relation of such conjugates to SMX-induced CDR is, therefore, unclear. Cribb et al. (1997) determined whether or not patients with a history of delayed-type immune-mediated reaction to sulfonamides had antibodies recognizing SMX-rat liver microsomal protein conjugates and/or native rat liver microsomal protein. Seventeen of 21 patients exhibited antibodies recognizing one or more native microsomal proteins, whereas only one subject had antibodies that recognized SMX-protein conjugates. These results suggest that these reactions are associated with antibodies that recognize specific microsomal protein epitopes rather than drug-protein conjugates. Similarly, in an analysis of AIDS patients with and without a history of TMP-SMX-induced CDR, we found no subject that demonstrated serum antibodies that recognized an SMX-albumin conjugate (T. P. Reilly and C. K. Svensson, unpublished observations).

While the incidence of a delayed-type immune-mediated reaction is markedly increased in HIV-infected subjects, evidence suggests there may be some important differences in the nature and predisposing factors for these reactions in this patient population. First, the fever and general exanthema manifested in many HIV-infected subjects upon treatment with TMP-SMX appear self-limiting, despite continued administration of the drug (Coopman and Stern, 1991; Roudier et al., 1994). Second, the incidence of CDR in this patient population appears to be dose-dependent (Schneider et al., 1995). Third, although numerous investigators have reported elaborate "desensitization" protocols (Papakonstantinou et al., 1988; White et al., 1989; Gluckenstein and Ruskin, 1995; Caumes et al., 1997; Demoly et al., 1998; Yoshizawa et al., 2000), the majority of patients experiencing a mild rash appear to tolerate re-challenge with TMP-SMX without recurrence of the CDR (Shafer et al., 1989; Carr et al., 1993a; Bonfanti et al., 2000). It

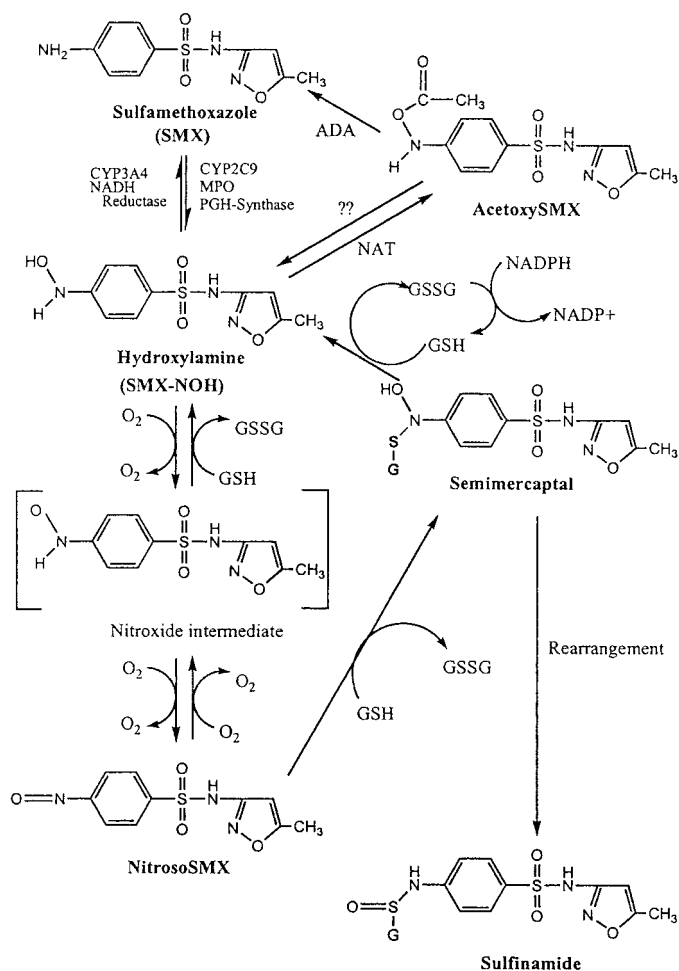


FIG. 13. Formation and disposition of sulfamethoxazole hydroxylamine. Acetylation of SMX-NOH results in the formation of acetoxy-SMX, which is rapidly converted back to SMX-NOH by an unknown enzymatic process. The major product of the reaction of nitroso-SMX with GSH is the semimercaptal, which is thiolatically cleaved rapidly to regenerate SMX-NOH. Rearrangement to the sulfonamide is a minor pathway. ADA, arylacetamide deacetylase; MPO, myeloperoxidase; NAT, *N*-acetyltransferase; PGH, prostaglandin H; ??, unknown enzymatic pathway. Adapted from Cribb et al. (1996a).

should be noted, however, that HIV-infected patients re-challenged with TMP-SMX have experienced serious and life-threatening reactions (Carr et al., 1993a; Coopman et al., 1993; Sanwo et al., 1996). Thus, re-challenge with a sulfonamide, even in the HIV-infected population, should only be undertaken in the absence of other therapeutic options and should occur under close medical supervision.

As described, the role of metabolic alterations as a predisposing factor in sulfonamide CDR has been demonstrated by several investigators in patients presumed to be HIV-negative (Shear et al., 1986; Rieder et al., 1988; Wolkenstein et al., 1995b). The results of similar investigations in the HIV-positive population have met with mixed results. Although Carr et al. (1993b) reported that the *in vitro* cytotoxicity of SMX-NOH was greater in HIV-infected patients with a history of CDR to TMP-SMX, we have provided evidence that suggests *in vitro* cytotoxicity is not a specific or sensitive marker for sulfonamide-induced CDR in HIV-infected patients (Reilly et al., 1999).

Numerous studies have demonstrated that the percentage of HIV-infected patients with a history of sulfonamide-induced CDR that exhibit the slow acetylator phenotype is greater than that found in patients with no history of CDRs (Kaufmann et al., 1996; Smith et al., 1998; Quirino et al., 1999). One group of investigators found no increase in the percentage of patients with the slow acetylator *genotype* among those who had experienced a sulfonamide-induced CDR (Delomenie et al., 1994). We recently compared the acetylator phenotype and genotype in a group of HIV-infected patients with and without a history of hypersensitivity to TMP-SMX. Of the subjects with a history of CDR, 64% displayed the slow acetylator genotype, compared with 29% without such a history (W. M. O'Neil, R. D. MacArthur, M. J. Farrough, M. A. Doll, A. J. Fretland, D. W. Hein, L. R. Crane, and C. K. Svensson, unpublished data). Lee et al. (1993) found that 27 of 29 (93%) AIDS patients with acute illness, but without an apparent history of CDR to sulfonamides, exhibited the slow acetylator phenotype, compared with 18 of 29 (64%) control patients. As the percentage of slow acetylators among stable AIDS patients did not differ from control subjects, these data suggested that acute illness in AIDS patients may reduce acetylation capacity. We, however, found no difference in the frequency of slow acetylators in AIDS patients with acute illness versus stable AIDS patients or control subjects (O'Neil et al., 2000). Moreover, we found no difference in the acetylator phenotype of subjects whose phenotype was determined during and after resolution of an opportunistic infection. Thus, it does not appear that patients with a CDR to sulfonamides exhibit a higher frequency of the slow acetylator phenotype as a consequence of disease-induced metabolic alterations.

Thus, investigations over the past decade have increased our understanding of the mechanisms involved

in sulfonamide-induced CDR. Although substantial evidence points to the importance of bioactivation of the parent arylamine, the role this process plays in predisposing subjects to CDRs remains unclear. Reasonable evidence indicates that T-cell activation is an essential step in the development of the most common reactions to this class of drugs. There is, however, much more that remains to be elucidated regarding the events that initiate an immune response during drug administration.

### B. Anticonvulsants

In 1934, Silber and Epstein reported a treatment that would, by most of today's clinicians, seem somewhat bizarre (Silber and Epstein, 1934). The investigators administered phenytoin (then known as phenylethylhydantoin) with the intent of evoking a hypersensitivity syndrome to treat Sydenham's chorea. It is now recognized that the *anticonvulsant hypersensitivity syndrome* (AHS) represents a potentially life-threatening reaction to a number of anticonvulsants, including phenytoin, carbamazepine, and phenobarbital. This syndrome is characterized by fever, generalized rash, and lymphadenopathy, but may present with other systemic complications (De Vriese et al., 1995; Vittorio and Muglia, 1995). The incidence of this syndrome is estimated to be between 1:1000 and 1:10,000 exposures (Gennis et al., 1991; Tennis and Stern, 1997). However, an isolated rash to anticonvulsants may occur in as many as 3 to 20% of patients receiving the drug (Chadwick et al., 1984; Zakrzewska and Ivanyi, 1988; Pelekanos et al., 1991; Konishi et al., 1993).

The majority of investigations into the AHS have focused on phenytoin. The most frequent clinical findings in phenytoin-induced AHS are rash (93%), fever (93%), lymphadenopathy (70%), hepatomegaly (57%), jaundice (43%), and periorbital/facial edema (23%) (Smythe and Umstead, 1989). The majority of cases reported occurred within 6 weeks of initiating therapy with the drug. The incidence of this syndrome does not appear to be related to age or phenytoin dose. As fever, rash, lymphadenopathy, and eosinophilia are commonly present, the reaction appears to be immune-mediated. The identification of drug-specific activated T-cell clones from peripheral blood of patients with the syndrome suggests the involvement of T-cell activation in mediating these reactions (Maria et al., 1994; Mauri-Hellweg et al., 1995; Maria and Victorino, 1997).

As with most CDRs, it has been postulated that bioactivation of phenytoin was necessary to initiate the cascade of events leading to a CDR or AHS. Spielberg et al. (1981b) demonstrated that bioactivation of phenytoin resulted in cytotoxicity toward human lymphocytes, which was enhanced by the inhibition of epoxide hydrolyase. Subsequently, incubation of lymphocytes from patients with phenytoin-induced AHS with phenytoin and a bioactivation system was found to result in more cell death than in lymphocytes from control subjects (Spiel-



berg et al., 1981a). Cells from siblings of patients with phenytoin-induced AHS also displayed a higher than normal sensitivity to phenytoin metabolites (Spielberg et al., 1981a; Gennis et al., 1991). This led to the suggestion that a familial deficiency in epoxide hydrolase predisposed subjects to development of the AHS. However, in subsequent studies no mutation in the gene for epoxide hydrolase has been found to be associated with this syndrome (Gaidigk et al., 1994; Green et al., 1995).

CDRs also represent the most frequent adverse effect with carbamazepine administration (Askmark and Wiholm, 1990). The median duration of therapy prior to development of a skin rash appears to be 1 month (Puig et al., 1996; Troost et al., 1996). Reported skin reactions include maculopapular, urticarial, erythematous, exfoliative, and eczematous-type reactions, as well as TEN (Friedmann et al., 1994). In an assessment of 65 cases of carbamazepine CDR, 23% of patients exhibited accompanying systemic manifestations (Troost et al., 1996). T-cell clones that proliferate in the presence of carbamazepine or one of its metabolites have been isolated from peripheral blood of patients with isolated cutaneous reactions or the anticonvulsant hypersensitivity syndrome (Troost et al., 1996). These observations support a role for a T-cell-mediated response in the elicitation of these reactions as well. As with other anticonvulsants, it has been suggested that liver bioactivation via an arene oxide is a critical step in the initiation of these reactions (Riley et al., 1989; Pirmohamed et al., 1992). It has been reported that bioactivated carbamazepine causes a higher incidence of cell death in vitro in peripheral blood mononuclear cells from patients with a history of CDR to the drug than from subjects with no such history (Pirmohamed et al., 1991; Friedmann et al., 1994). Recently, it has been suggested that a reactive iminoquinone intermediate, potentially formed in circulating immune cells, may be a more likely candidate for the active species initiating the adverse reactions (Ju and Utrecht, 1999). As described earlier, such postulates suffer from the common deficiency of why reactive metabolite formed distant from the skin would evoke skin reactions as the most common manifestation. This may be resolved by the observation that cytochrome P450s that bioactivate carbamazepine have also been identified in human epidermis (Wolkenstein et al., 1998), the site of CDR manifestations.

Lamotrigine is another anticonvulsant associated with a significant frequency of CDR ( $\geq 10\%$ ), including TEN (Iannetti et al., 1998; Page et al., 1998; Schlienger et al., 1998; Faught et al., 1999). Based upon postmarketing data, the frequency of SJS or TEN is estimated to be 1:1000 and 3:1000 for adults and children, respectively (Page et al., 1998). The likelihood of TEN appears increased in the presence of concomitant therapy with valproic acid. Since valproic acid inhibits the metabolism of lamotrigine, this suggests the CDR may be serum-concentration-dependent (Yuen et al., 1992).

*C. Nonsteroidal Anti-Inflammatory Drugs*

NSAIDs are a commonly used class of over-the-counter and prescription medications, and therefore, isolating an NSAID as the causative factor of a drug eruption can be a clinical challenge. Alanko et al. (1989) found NSAIDs to be the causative agent in 27% of all adverse drug eruptions. Most cutaneous reactions of this class are mild and include pruritus, urticaria, morbilliform rashes, and pseudoporphyria (Table 3) (Bigby and Stern, 1985; Roth et al., 1989). Rarely, more severe reactions including SJS and TEN may occur.

Urticaria is the most common cutaneous adverse reaction of aspirin. It has been implicated in 10% of cases of acute urticaria and may cause worsening of chronic urticaria (Roth et al., 1989). NSAIDs other than salicylates may also cause urticaria, particularly in patients who have experienced a previous urticarial reaction to aspirin.

Pseudoporphyria has been reported in association with several of the newer NSAIDs, including naproxen, nabumetone, and ketoprofen (Green and Manders, 2001). The skin lesions may be indistinguishable from porphyria cutanea tarda, but in pseudoporphyria there is no detectable abnormality in porphyrin metabolism. Skin lesions occur as small vesicles and bullae at areas of sun exposure, particularly the dorsal hands, and may heal with scarring and milia formation. The photodistribution of skin lesions suggests that either the drug or its metabolite causes a phototoxic reaction following exposure to long wavelength ultraviolet light (320–400 nm). Unlike true porphyria cutanea tarda, associated findings in pseudoporphyria, including hypertrichosis, hyperpigmentation, and sclerodermoid changes, are uncommon (Green and Manders, 2001).

TABLE 3  
*CDR reported to be associated with various drugs*

NSAIDs	Antiretrovirals	Cephalosporins	Amoxicillin/Ampicillin
Fixed drug eruptions	Acne	Acute generalized exanthematous pustulosis	Acute generalized exanthematous pustulosis
Lichenoid eruption	Lipodystrophy	Exfoliative dermatitis	Dryg-induced pemphigus
Morbilloform eruption	Pigmentation	Fixed drug eruption	Fixed durg eruption
Photosensitivity	Pruritis	Morbilloform eruption	Morbilloform eruption
Pruritis	SJS/TEN	Pruritis ani	Pustular eruption (localized)
Pseudoporphyria	Urticaria	Serum sickness-like reaction	Serum sickness-like reaction
SJS/TEN	Vasculitis	Serum sickness-like reaction	Serum sickness-like reaction
Urticaria		Vulvovaginitis	SJS

NSAIDs are commonly implicated in TEN, accounting for 36% of cases of TEN over a 4-year period in France (Roujeau, 1987). The increased availability of NSAIDs may be at least partly responsible for the high percentage of TEN due to NSAIDs. In 1973, four NSAIDs were available by prescription; by 1982, twelve prescription NSAIDs were available (Bigby and Stern, 1985). Several NSAIDs appear to have a higher risk of severe ADRs. Sulindac causes rash in 3 to 9% of patients, including several cases of SJS and TEN (Bigby and Stern, 1985). Similarly, oxicam derivatives are associated with both SJS and TEN (Roujeau et al., 1995).

#### D. Antiretroviral Agents

Antiviral agents are less commonly implicated in ADRs than antibiotics (Table 3) (Breathnach, 1998); nevertheless, severe drug reactions occur more frequently in patients with HIV infection than in the general population. Overall, SJS and TEN are 100 to 1000 times more likely for a given drug exposure in patients with AIDS (Odom et al., 2000). Because HIV-infected patients are often treated with multiple antiretroviral medications, as well as other medications including sulfonamides, identification of the causative agent can be challenging. However, one antiretroviral in particular, nevirapine, has emerged as a common cause of severe adverse cutaneous reactions in HIV-infected patients.

Nevirapine is a non-nucleoside reverse transcriptase inhibitor approved by the Food and Drug Administration in 1996 for treatment of HIV infection. Cutaneous drug eruptions including morbilliform rash, urticaria, hypersensitivity syndrome, SJS, and TEN are the most frequent side effects of the medication and may be seen in as many as 35% of patients (Barner and Myers, 1998). Since its introduction, nevirapine has been directly responsible for at least 23 cases of SJS and TEN and at least three deaths (Warren et al., 1998; Antón et al., 1999; Wetterwald et al., 1999). In the four major development trials of nevirapine, 6.6% of patients experienced a severe or life-threatening eruption (Barner and Myers, 1998).

Because the risk of severe CDR appears to be greatest within the first several weeks of treatment, standard recommendations are to start nevirapine at a half-dose (200 mg) for the first 2 weeks. Antón et al. (1999) compared this regimen to an even more gradual escalating schedule (100 mg  $\times$  1 week, 200 mg  $\times$  1 week, 300 mg  $\times$  1 week, then full dose 400 g) and found that 8.5% of 166 patients on the standard schedule had to discontinue the medication due to rash compared with 2.1% of 97 patients using a more gradual taper. Tolerance induction with graded dosing of nevirapine in conjunction with antihistamines has also been successful in two of three patients who had previously failed treatment due to non-bullous cutaneous reactions (Demoly et al., 1999).

The risk of severe rash from other non-nucleoside reverse transcriptase inhibitors appears to be less than

that of nevirapine. In addition, two patients who developed a hypersensitivity reaction to nevirapine were treated with oral steroids and switched successfully to efavirenz (Podzamczek et al., 2000). The use of oral steroids (prednisone 40 mg/day) for 14 days at the start of treatment with nevirapine has actually demonstrated an increased incidence and severity of CDR and is not recommended (Viramune package insert; Roxane Laboratories, Inc., Columbus, OH).

Lipodystrophy is a recently characterized syndrome of acral fat wasting, central fat deposition, and glucose and lipid abnormalities seen in HIV-infected patients receiving treatment with one or more protease inhibitors. It does not appear to be an idiosyncratic CDR. Carr et al. (1998) identified lipodystrophy in 83% of 113 HIV-infected patients treated with protease inhibitors versus 4% of controls (HIV-infected, not using protease inhibitors). These cutaneous changes occurred after a mean of 21 months of therapy and failed to resolve following cessation of treatment (Carr et al., 1998).

#### E. Cephalosporins

The cephalosporins are  $\beta$ -lactam antibiotics that differ from penicillin by the substitution of the five-membered thiazolidine ring common to the penicillin group with a six-membered dihydrothiazine ring. The risk of adverse cutaneous reaction to cephalosporins in a patient with a history of penicillin allergy is controversial, but appears to be quite low. Nevertheless, human studies have demonstrated that cross-reactivity does occur, including life-threatening anaphylaxis (Weiss, 1992).

Both cephalosporins and the penicillins have been implicated in inducing a pemphigus-like syndrome (Table 3) (Fitzpatrick, 1992; Breathnach, 1998; Crowson and Magro, 1999). This syndrome is also induced by thiol drugs, including captopril, D-penicillamine, and gold sodium thiomalate. It is characterized by flaccid bullae clinically indistinguishable from pemphigus vulgaris that develop within the first few weeks of drug therapy. Direct immunofluorescence demonstrates IgG antibodies targeting the keratinocyte desmosomal components desmoglein I or III in 90% of patients. Serum antibodies are detected by indirect immunofluorescence in approximately 70% of patients. Resolution after drug cessation is variable—some cases will spontaneously resolve, whereas other patients will continue to develop new lesions (Fitzpatrick, 1992). In patients in whom antibodies are not identified, the skin lesions tend to regress following therapy, suggesting a direct toxic effect on keratinocyte adhesion rather than immunoactivation (Crowson and Magro, 1999).

Cefaclor is a common cause of morbilliform eruption in children and, less commonly, a serum sickness-like reaction. Patients with serum sickness-like reaction develop fever, arthralgias, and skin eruption 1 to 3 weeks after starting drug therapy (Knowles and Shear, 2001). There is evidence that biotransformation of cefaclor is

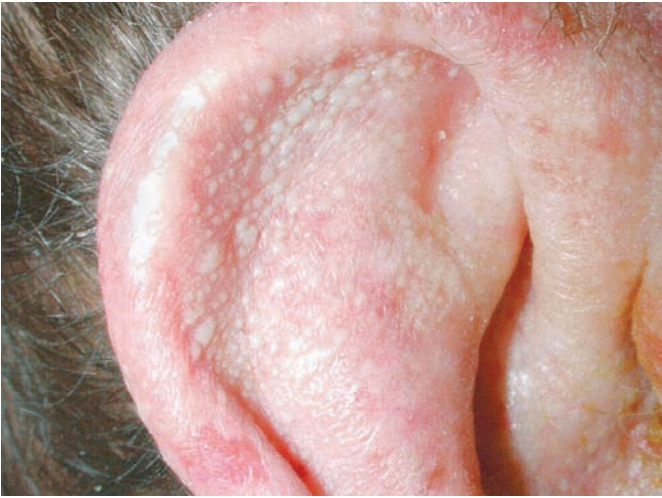

FIG. 14. Acute generalized exanthematous pustulosis. The patient developed several hundred small non-follicular based pustules after the use of azithromycin. The eruption began on the head and neck and spread over 24 h to cover the torso and proximal extremities.

necessary to elicit a serum sickness-like reaction and that a heritable defect of metabolism may be involved (Kearns et al., 1994). Patients who develop a serum sickness-like reaction following the use of cefaclor should avoid  $\beta$ -lactam antibiotics in the future (Grammer, 1996).

#### F. Ampicillin / Amoxicillin

Penicillin and its derivatives are among the most common cause of allergic drug reactions, the phenotype of which may vary from a morbilliform eruption to anaphylaxis (Table 3) (Breathnach, 1998). Fatality from penicillin anaphylaxis results in 400 to 800 deaths/year (Weiss, 1992). Patients with a history of reaction to penicillin have a four to six times increased risk of reaction to future treatments compared with the normal population; however, many patients are incorrectly labeled as penicillin allergic or may have lost their sensitivity (Weiss, 1992).

Ampicillin and amoxicillin are the penicillins most commonly implicated in morbilliform drug reactions. The high cutaneous reaction rate may be due to the di-acyl side chain of these compounds that results in the formation of linear polymers. The incidence of cutaneous drug eruption due to ampicillin and amoxicillin is particularly high in patients with infectious mononucleosis, cytomegalovirus, or acute lymphocytic leukemia (60–100%) (Weiss, 1992).

Acute generalized exanthematous pustulosis is a distinct reaction pattern commonly caused by  $\beta$ -lactam and macrolide antibiotics (Beylot et al., 1996; Knowles and Shear, 2001). This unique reaction pattern is characterized by non-follicular based pustules on an erythematous background that arise within 2 weeks of drug exposure (Fig. 14). The eruption usually begins on the face or intertriginous areas and spreads rapidly to affect the entire body. In contrast to pustular psoriasis, polymor-

phous lesions, including EM-like lesions and purpura, are common (Beylot et al., 1996). Fever and leukocytosis are also clinical clues to the diagnosis of acute generalized exanthematous pustulosis. Histology characteristically demonstrates an intraepidermal spongiform pustule with eosinophils.

*Acknowledgments.* This work was supported in part by Grant AI41395 from the National Institutes of Health to Dr. Svensson. The assistance of Ramona Douglas and the staff of Shiffman Medical Library at Wayne State University in literature retrieval is gratefully acknowledged. We thank Dr. Timothy P. Reilly for helpful review of the manuscript.

#### REFERENCES

- Acostamadiedo JM, Perniciaro C, and Rogers RS (1998) Phenytoin-induced linear IgA bullous disease. *J Am Acad Dermatol* **38**:352–356.
- Ahlstedt S and Kristofferson A (1982) Immune mechanisms of induction of penicillin allergy, in *Recent Trends in Allergen and Complement Research. Progress in Allergy* (Kallos P ed) vol 30, pp 67–134, Karger, Basel.
- Alanko K, Stubb S, and Kauppinen K (1989) Cutaneous drug reactions: clinical types and causative agents. *Acta Derm Venereol* **69**:223–226.
- Amagai M, Klaus-Kotvun V, and Stanley JR (1991) Autoantibodies against a novel epithelial cadherin in pemphigus vulgaris, a disease of cell adhesion. *Cell* **67**:869–877.
- Anon (2000) EMEA Public Statement on Viramune (Nevirapine)—Severe and Life-Threatening Cutaneous and Hepatic Reactions., vol. 2001, The European Agency for the Evaluation of Medicinal Products, London.
- Antón P, Soriano V, Jiménez-Nácher I, Rodríguez-Rosado R, Dona MC, Barreiro PM, and González-Lahoz J (1999) Incidence of rash and discontinuation of nevirapine using two different escalating doses. *AIDS* **13**:524–525.
- Arndt KA and Jick H (1976) Rates of cutaneous reactions to drugs. A report from the Boston Collaborative Drug Surveillance Program. *J Am Med Assoc* **235**:918–922.
- Askmark H and Wiholm B (1990) Epidemiology of adverse reactions to carbamazepine as seen in a spontaneous reporting system. *Acta Neurol Scand* **81**:131–140.
- Baldo BA (1999) Penicillins and cephalosporins as allergens—structural aspects of recognition and cross-reactions. *Clin Exp Allergy* **29**:744–749.
- Baldo BA and Pharm NH (1994) Structure-activity studies of drug-induced anaphylactic reactions. *Chem Res Toxicol* **7**:703–721.
- Baldo BA, Pharm NH, and Weiner J (1995) Detection and side-chain specificity of IgE antibodies to flucloxacillin in allergic subjects. *J Mol Recognit* **8**:171–177.
- Barbaud A, Bene M-C, and Faure G (1997) Immunological physiopathology of cutaneous adverse drug reactions. *Eur J Dermatol* **7**:319–323.
- Barner A and Myers M (1998) Nevirapine and rashes. *Lancet* **351**:1133.
- Battegay M, Opravil M, Wuthrich B, and Luthy R (1989) Rash with amoxicillin-clavulanate therapy in HIV-infected patients. *Lancet* **334**:1100.
- Bayard PJ, Berger TG, and Jacobson MA (1992) Drug hypersensitivity reactions and human immunodeficiency virus disease. *J Acquir Immune Defic Syndr* **5**:1237–1257.
- Berg PA and Daniel PT (1987) Co-trimoxazole-induced liver injury—an analysis of cases with hypersensitivity-like reactions. *Infection* **15**:S259–S263.
- Beylot C, Doutre M-S, and Beylot-Barry M (1996) Acute generalized exanthematous pustulosis. *Semin Cutan Med Surg* **15**:244–249.
- Bigby M, Jick S, Jick H, and Arndt K (1986) Drug-induced cutaneous reactions. *J Am Med Assoc* **256**:3358–3363.
- Bigby M and Stern R (1985) Cutaneous reactions to non-steroidal anti-inflammatory drugs. *J Am Acad Dermatol* **12**:866–876.
- Blickenstaff RD, Perry HO, and Peters MS (1988) Linear IgA deposition associated with cutaneous varicella-zoster infection: a case report. *J Cutan Pathol* **15**:49–52.
- Blum RN, Miller LA, Gaggini LC, and Cohn DL (1992) Comparative trial of dapsone versus trimethoprim/sulfamethoxazole for primary prophylaxis of *Pneumocystis carinii* pneumonia. *J Acquir Immune Defic Syndr* **5**:341–347.
- Boismenu R and Havran WL (1997) An innate view of  $\gamma\delta$  T cells. *Curr Opin Immunol* **9**:57–63.
- Boismenu R and Havran WL (1998)  $\gamma\delta$  T cells in host defense and epithelial cell biology. *Clin Immunol Immunopathol* **86**:121–133.
- Bonfanti P, Pusterla L, Parazzini F, Libanore M, Cagni AE, Franzetti M, Faggion I, Landonio S, and Quirino T (2000) The effectiveness of desensitization versus rechallenge treatment in HIV-positive patients with previous hypersensitivity to TMP-SMX: a randomized multicentric study. *Biomed Pharmacother* **54**:45–49.
- Boyd AW, Wawryk SO, Burns GF, and Fecondo JV (1988) Intercellular adhesion molecule 1 (ICAM-1) has a central role in cell-cell immune mechanisms. *Proc Natl Acad Sci USA* **85**:3095–3099.
- Breathnach SM (1998) Drug reactions, in *Rook/Wilkinson/Ebling Textbook of Dermatology* (Champion RH, Burton JL, Burns DA, and Breathnach SM eds) pp 3349–3517, Blackwell Science, Malden, MA.
- Buckman SY, Gresham A, Hale P, Hruza G, Anast J, Masferrer J, and Pentland AP (1998) COX-2 expression is induced by UVB exposure in human skin: Implications for the development of skin cancer. *Carcinogenesis* **19**:723–729.
- Camins A, Diez-Fernandez C, and Prieto P (1999) Cell-surface expression of heat shock proteins in dog neutrophils after oxidative stress. *Toxicol In Vitro* **13**:437–443.
- Carr A (1997) Role of desensitisation for drug hypersensitivity in patients with HIV infection. *Drug Safety* **17**:119–126.

- Carr A, Penny R, and Cooper DA (1993a) Efficacy and safety of rechallenge with low-dose trimethoprim-sulphamethoxazole in previously hypersensitive HIV-infected patients. *AIDS* **7**:65-71.
- Carr A, Samaras K, Thorisdottir A, Kaufmann GR, Chisholm DJ, Cooper DA (1998) Diagnosis, prediction, and natural course of HIV-1 protease-inhibitor-associated lipodystrophy, hyperlipidemia, and diabetes mellitus: a cohort study. *Lancet* **353**: 2093-2099.
- Carr A, Tindall B, Penny R, and Cooper DA (1993b) In vitro cytotoxicity as a marker of hypersensitivity to sulphamethoxazole in patients with HIV. *Clin Exp Immunol* **94**:21-25.
- Carrington DM, Earl HS, and Sullivan TJ (1987) Studies of human IgE to a sulfonamide determinant. *J Allergy Clin Immunol* **79**:442-447.
- Castren K, Pienimäki P, Arvela P, and Vahakangas K (1996) Metabolites and DNA-binding of carbamazepine and oxcarbazepine in vitro by rat liver microsomes. *Hum Exp Toxicol* **15**:577-582.
- Caumes E, Guermontez G, Lecomte C, Katlama C, and Bricaire F (1997) Efficacy and safety of desensitization with sulfamethoxazole and trimethoprim in 48 previously hypersensitive patients infected with human immunodeficiency virus. *Arch Dermatol* **133**:465-469.
- Centers for Disease Control (2001) Serious adverse events attributed to nevirapine regimens for postexposure prophylaxis after HIV exposure—Worldwide, 1997-2000. *Morb Mortal Wkly Rep* **49**:1153-1156.
- Chadwick D, Shaw MD, Foy P, Rawlins MD, and Turnbull DM (1984) Serum anticonvulsant concentrations and the risk of drug induced skin eruptions. *J Neurol Neurosurg Psychiatry* **47**:642-644.
- Chan H-L, Stern RS, Arndt KA, Langlois J, Jick SA, Jick H, and Walker AM (1990) The incidence of erythema multiforme, Stevens-Johnson syndrome, and toxic epidermal necrolysis. A population-based study with particular reference to reactions caused by drugs among outpatients. *Arch Dermatol* **126**:43-47.
- Coleman JW and Blanca M (1998) Mechanisms of drug allergy. *Immunol Today* **19**:196-198.
- Coleman JW, Foster AL, Yeung JHK, and Park BK (1988) Drug-protein conjugates XV. A study of the disposition of D-penicillamine in the rat and its relationship to immunogenicity. *Biochem Pharmacol* **37**:737-742.
- Coleman MD, Breckenridge AM, and Park BK (1989) Bioactivation of dapsone to a cytotoxic metabolite by human hepatic microsomal enzymes. *Br J Clin Pharmacol* **28**:389-395.
- Coopman SA, Johnson RA, Platt R, and Stern RS (1993) Cutaneous disease and drug reactions in HIV infection. *N Engl J Med* **328**:1670-1674.
- Coopman SA and Stern RS (1991) Cutaneous drug reactions in human immunodeficiency virus infection. *J Am Med Assoc* **271**:714-717.
- Cribb AE, Lee BL, Trepanier LA, and Spielberg SP (1996a) Adverse reactions to sulphonamide and sulphonamide-trimethoprim antimicrobials: clinical syndromes and pathogenesis. *Adver Drug React Toxicol Rev* **15**:9-50.
- Cribb AE, Miller M, Leeder JS, Hill J, and Spielberg SP (1991) Reactions of the nitroso and hydroxylamine metabolites of sulfamethoxazole with reduced glutathione. Implications for idiosyncratic toxicity. *Drug Metab Dispos* **19**:900-906.
- Cribb AE, Nakamura H, Grant DM, Miller MA, and Spielberg SP (1993) Role of polymorphic and monomorphic human arylamine N-acetyltransferases in determining sulfamethoxazole metabolism. *Biochem Pharmacol* **45**:1277-1282.
- Cribb AE, Nuss CE, Alberts DW, Lamphere DB, Grant DM, Grossman SJ, and Spielberg SP (1996b) Covalent binding of sulfamethoxazole reactive metabolites to human and rat liver subcellular fractions assessed by immunochemical detection. *Chem Res Toxicol* **9**:500-507.
- Cribb AE, Pohl LR, Spielberg SP, and Leeder JS (1997) Patients with delayed-onset sulfonamide hypersensitivity reactions have antibodies recognizing endoplasmic reticulum luminal proteins. *J Pharmacol Exp Ther* **282**:1064-1071.
- Cribb AE and Spielberg SP (1990a) Hepatic microsomal metabolism of sulfamethoxazole to the hydroxylamine. *Drug Metab Dispos* **18**:784-787.
- Cribb AE and Spielberg SP (1990b) An in vitro investigation of predisposition to sulphonamide idiosyncratic toxicity in dogs. *Vet Res Commun* **14**:241-252.
- Cribb AE and Spielberg SP (1992) Sulfamethoxazole is metabolized to the hydroxylamine in humans. *Clin Pharmacol Ther* **51**:522-526.
- Crowson AN and Magro CM (1999) Recent advances in the pathology of cutaneous drug eruptions. *Dermatol Clin* **17**:537-560.
- Cumberbatch M, Dearman RJ, and Kimber I (1997a) Interleukin  $\beta$  and the stimulation of Langerhans cell migration: comparisons with tumour necrosis factor  $\alpha$ . *Arch Dermatol Res* **289**:277-284.
- Cumberbatch M, Dearman RJ, and Kimber I (1997b) Langerhans cells require signals from both tumour necrosis factor- $\alpha$  and interleukin- $\beta$  for migration. *Immunology* **92**:388-395.
- Cumberbatch M, Dearman RJ, and Kimber I (1999) Inhibition by dexamethasone of Langerhans cell migration: influence of epidermal cytokine signals. *Immunopharmacol* **41**:235-243.
- Cumberbatch M, Fielding I, and Kimber I (1994) Modulation of epidermal Langerhans' cell frequency by tumour necrosis factor- $\alpha$ . *Immunology* **81**:395-401.
- Cumberbatch M and Kimber I (1995) Tumour necrosis factor- $\alpha$  is required for accumulation of dendritic cells in draining lymph nodes and for optimal contact sensitization. *Immunology* **84**:31-35.
- Das MG, Bailey MJ, and Wickham JEA (1988) Toxic epidermal necrolysis and trimethoprim. *Br Med J* **296**:1604-1605.
- Delomenie C, Grant DM, Mathelier-fusade P, Jacomet C, Leynadier F, Jacqz-Aigrain E, Rozenbaum W, Krishnamoorthy R, and Dupret J-M (1994) N-acetylation genotype and risk of severe reactions to sulphonamides in AIDS patients. *Br J Clin Pharmacol* **38**:581.
- Demoly P, Messaad D, Fabre J, Reynes J, and Bousquet J (1999) Nevirapine-induced cutaneous hypersensitivity reactions and successful tolerance induction. *Allergy Clin Immunol* **104**:504-505.
- Demoly P, Messaad D, Sahla H, Fabre J, Faucherre V, Andre P, Reynes J, Godard P, and Bousquet J (1998) Six-hour trimethoprim-sulfamethoxazole-graded challenge in HIV-infected patients. *J Allergy Clin Immunol* **102**:1033-1036.
- De Vriese SP, Philippe J, Van Renterghem DM, De Cuyper CA, Hindryckx PHF, Matthys EG, and Louagie A (1995) Carbamazepine hypersensitivity syndrome: report of 4 cases and review of the literature. *Medicine* **74**:144-151.
- Didier A, Cador D, Bondgrand P, Furstoss R, Fourneron P, Senft M, Philip-Joet F, Charpin J, and Vervloet D (1987) Role of quaternary ammonium ion determinants in allergy to muscle relaxants. *J Allergy Clin Immunol* **79**:578-584.
- Dujovne DA, Chan CH, and Zimmerman HJ (1967) Sulfonamide hepatic injury. *N Engl J Med* **377**:785-788.
- Epstein JH (1999) Phototoxicity and photoallergy. *Semin Cutan Med Surg* **18**:274-284.
- Evans AS (1982) The clinical illness promotion factor: a third ingredient. *Yale J Biol Med* **55**:193-199.
- Faich GA, Knapp D, Dreis M, and Turner W (1987) National adverse drug reaction surveillance. *J Am Med Assoc* **257**:2068-2070.
- Fattinger K, Roos M, Vergeres P, Hostenstein C, Kind B, Masche U, Stocker DN, Braunschweig S, Kullak-Ublick GA, Galeazzi RL, Follath F, Gasser T, and Meier PJ (2000) Epidemiology of drug exposure and adverse drug reactions in two Swiss departments of internal medicine. *Br J Clin Pharmacol* **49**:158-167.
- Faught E, Morris G, Jacobson M, French J, Harden C, Montouris G, and Rosenfeld W (1999) Adding lamotrigine to valproate: incidence of rash and other adverse effects. *Epilepsia* **40**:1135-1140.
- Fitzpatrick JE (1992) New histopathologic findings in drug eruptions. *Dermatol Clin* **10**:19-36.
- Foster AL, Park BK, and Coleman JW (1987) A specific enzyme-linked immunosorbent assay for definition of the IgG antibody response to disulphide-conjugated D-penicillamine in the rabbit. *Int Arch Allergy Appl Immunol* **84**:271-276.
- Friedmann PS, Strickland I, Pirmohamed M, and Park BK (1994) Investigation of mechanisms in toxic epidermal necrolysis induced by carbamazepine. *Arch Dermatol* **130**:598-604.
- Furst SM and Utrecht JP (1993) Carbamazepine metabolism to a reactive intermediate by the myeloperoxidase system of activated neutrophils. *Biochem Pharmacol* **45**:1267-1275.
- Furst SM and Utrecht JP (1995) The effect of carbamazepine and its reactive metabolite, 9-acridine carboxaldehyde, on immune cell function in vitro. *Int J Immunopharmacol* **17**:445-452.
- Gaidigk A, Spielberg SP, and Grant DM (1994) Characterization of the microsomal epoxide hydrolase gene in patients with anticonvulsant adverse drug reactions. *Pharmacogenetics* **4**:142-153.
- Gaspari AA (1993) Advances in understanding contact hypersensitivity. *Am J Contact Dermatol* **4**:138-149.
- Gebhardt M and Wollina U (1997) Allergy testing in serious cutaneous reactions - harmful or beneficial? *Contact Derm* **37**:282-285.
- Gennis MA, Vermuri R, Burns EA, Hill JV, Miller MA, and Spielberg SP (1991) Familial occurrence of hypersensitivity to phenytoin. *Am J Med* **91**:631-634.
- Gluckenstein D and Ruskin J (1995) Rapid oral desensitization to trimethoprim-sulfamethoxazole (TMP-SMXZ): use in prophylaxis for *Pneumocystis carinii* pneumonia in patients with AIDS who were previously intolerant to TMP-SMZ. *Clin Infect Dis* **20**:849-853.
- Godfrey K, Wojnarowska F, and Leonard J (1990) Linear IgA disease of adults: association with lymphoproliferative malignancy and possible role of other triggering factors. *Br J Dermatol* **123**:447-452.
- Goebel C, Vogel C, Wulferink M, Mittmann S, Sachs B, Schraa S, Abel J, Degen G, Utrecht J, and Gleichmann E (1999) Procainamide, a drug causing lupus, induces prostaglandin H synthase-2 and formation of T cell-sensitizing drug metabolites in mouse macrophages. *Chem Res Toxicol* **12**:488-500.
- Gonzalez-Martin G, Yanez CG, Gonzalez-Contreras L, and Labarca J (1999) Adverse drug reactions (ADRs) in patients with HIV infection. A prospective study. *Int J Clin Pharmacol Ther* **37**:34-40.
- Goodnow CC (1996) Balancing immunity and tolerance: Deleting and tuning lymphocyte repertoires. *Proc Natl Acad Sci USA* **93**:2264-2271.
- Grammer LC (1996) Cefaclor serum sickness. *J Am Med Assoc* **275**:1152-1153.
- Green JJ and Manders SM (2001) Pseudoporphyria. *J Am Acad Dermatol* **44**:100-109.
- Green VJ, Pirmohamed M, Kitteringham NR, Gaedigk A, Grant DM, Boxer M, Burchell B, and Park BK (1995) Genetic analysis of microsomal epoxide hydrolase in patients with carbamazepine hypersensitivity. *Biochem Pharmacol* **50**, 1353-1359.
- Griffiths CEM and Nickoloff BJ (1989) Keratinocyte intercellular adhesion molecule-1 (ICAM-1) expression precedes dermal T lymphocytic infiltration in allergic contact dermatitis (Rhus dermatitis). *Am J Pathol* **135**:1045-1053.
- Gruchalla RS (2000) Understanding drug allergies. *J Allergy Clin Immunol* **105**: S637-S644.
- Gruchalla RS, Pesenko RD, Do TT, and Skiest DJ (1998) Sulfonamide-induced reactions in desensitized patients with AIDS - The role of covalent protein hapteneation by sulfamethoxazole. *J Allergy Clin Immunol* **101**:371-378.
- Gruchalla RS and Sullivan TJ (1991) Detection of human IgE to sulfamethoxazole by skin testing with sulfamethoxazolyl-poly-L-tyrosine. *J Allergy Clin Immunol* **88**: 784-792.
- Gueniche A, Viac J, Lizard G, Charveron M, and Schmitt D (1994a) Effect of nickel on the activation state of normal human keratinocytes through interleukin 1 and intercellular adhesion molecule 1 expression. *Br J Dermatol* **131**:250-256.
- Gueniche A, Viac J, Lizard G, Charveron M, and Schmitt D (1994b) Effect of various metals on intercellular adhesion molecule-1 expression and tumour necrosis factor alpha production by normal keratinocytes. *Arch Dermatol Res* **286**:466-470.
- Harle DG and Baldo BA (1990) Identification of penicillin allergenic determinants that bind IgE antibodies in the sera of subjects with penicillin allergy. *Mol Immunol* **27**:1063-1071.
- Harle DG, Baldo BA, and Wells JV (1988) Drugs as allergens: detection and combining site specificities of IgE antibodies to sulfamethoxazole. *Mol Immunol* **25**: 1347-1354.

- Haverkos HW, Amsel Z, and Drotman DP (1991) Adverse virus-drug reactions. *Rev Infect Dis* **13**:697-704.
- Hertl M, Jugert F, and Merck HF (1995) CD8+ dermal T cells from a sulphamethoxazole-induced bullous exanthem proliferate in response to drug-modified liver microsomes. *Br J Dermatol* **132**:215-220.
- Ho TTY, Wong KH, Chan KCW, and Lee SS (1998) High incidence of nevirapine-associated rash in HIV-infected Chinese. *AIDS* **12**:2082-2083.
- Horton H, Weston SD, and Hewitt Cra (1998) Allergy to antibiotics: T-cell recognition of amoxicillin is HLA-DR restricted and does not require antigen processing. *Allergy* **53**:83-88.
- Iannetti P, Raucci U, Zuccaro P, and Pacifici R (1998) Lamotrigine hypersensitivity in childhood epilepsy. *Epilepsia* **39**:502-507.
- Ibia EO, Schwartz RH, and Widemann BL (2000) Antibiotic rashes in children. *Arch Dermatol* **136**:849-854.
- Ibrahim MAA, Chain BM, and Katz DR (1995) The injured cell: the role of the dendritic cell system as a sentinel receptor pathway. *Immunol Today* **16**:181-186.
- Janeway CA, Travers P, Walport M, and Capra JD (1999) *Immunobiology. The Immune System in Health and Disease*, Garland Publishing, New York.
- Ju C and Utrecht JP (1999) Detection of 2-hydroxyiminostilbene in the urine of patients taking carbamazepine and its oxidation to a reactive iminoquinone intermediate. *J Pharmacol Exp Ther* **288**:51-56.
- Kalish RS, LaPorte A, Wood JA, and Johnson KL (1994) Sulfonamide-reactive lymphocytes detected at very low frequency in the peripheral blood of patients with drug-induced eruptions. *J Allergy Clin Immunol* **94**:465-472.
- Kaufmann GR, Wenk M, Taeschner W, Peterli B, Gyr K, Meyer UA, and Haefeli WE (1996) N-Acetyltransferase 2 polymorphism in patients infected with human immunodeficiency virus. *Clin Pharmacol Ther* **60**:62-67.
- Kearns GL, Wheeler JG, Childree SH, and Letzig LG (1994) Serum sickness-like reactions to cefaclor: role of hepatic metabolism and individual susceptibility. *J Pediatr* **125**:805-811.
- Kimber I (1996) The skin immune system, in *Dermatotoxicology* (Marzulli F and Maibach H eds) pp 131-141, Taylor & Francis, Washington.
- Kimber I and Dearman RJ (1996) Contact hypersensitivity: immunological mechanisms, in *Toxicology of Contact Hypersensitivity* (Kimber I and Maurer T eds) pp 4-25, Taylor & Francis, London.
- Kimber I, Dearman RJ, Cumberbatch M, and Huby RJD (1998) Langerhans cells and chemical allergy. *Curr Opin Immunol* **10**:614-619.
- Kimber I, Holliday MR, and Dearman RJ (1995) Cytokine regulation of chemical sensitization. *Toxicol Lett* **82/83**:491-496.
- Klein PA and Callen JP (2000) Drug-induced linear IgA bullous dermatosis after vancomycin discontinuance in a patient with renal insufficiency. *J Am Acad Dermatol* **42**:316-323.
- Klemola E (1970) Hypersensitivity reactions to ampicillin in cytomegalovirus mononucleosis. *Scand J Infect Dis* **2**:29-31.
- Knowles SR and Shear NH (2001) Drug hypersensitivity syndromes, in *Comprehensive Dermatologic Drug Therapy* (Wolverton SE ed) pp 872-884, W. B. Saunders Company, Philadelphia.
- Kochevar IE and Harber LC (1977) Photoreactions of 3,3',4'-tetrachlorosalicylanilide with proteins. *J Invest Dermatol* **68**:151-156.
- Konishi T, Naganuma Y, Hongo K, Murakami M, Yamatani M, and Okada T (1993) Carbamazepine-induced skin rash in children with epilepsy. *Eur J Pediatr* **152**:605-608.
- Koulu L, Kusumi A, Steinberg MS, Klaus-Kotvun V, and Stanley Jr (1984) Human autoantibodies against a desmosomal core protein in pemphigus foliaceus. *J Exp Med* **160**:1509-1518.
- Kovacs JA, Hiemenz JW, Macher AM, Stover D, Murray HW, Shelhamer J, Lane HC, Urmacher C, Honig C, Longo DL, Parker MM, Natanson C, Parrillo JE, Fauci AS, Pizzo PA, and Masur H (1984) *Pneumocystis carinii* pneumonia: a comparison between patients with the acquired immunodeficiency syndrome and patients with other immunodeficiencies. *Ann Intern Med* **100**:663-671.
- Kuechle MK, Hutton KP, and Muller SA (1994a) Angiotensin-converting enzyme inhibitor-induced pemphigus: three case reports and literature review. *Mayo Clin Proc* **69**:1166-1171.
- Kuechle MK, Stegemier E, Maynard B, Gibson LE, Leiferman KM, and Peters MS (1994b) Drug-induced linear IgA bullous dermatosis: report of six cases and review of the literature. *J Am Acad Dermatol* **30**:187-192.
- Kwok MCO, Lanctot KL, Shear NH, and Naranjo CA (1994) Enhanced computerized Bayesian assessment of suspected drug rashes with 'BARDI-Q&A'. *Can J Clin Pharmacol* **1**:19-26.
- Lai WG, Zahid N, and Utrecht JP (1999) Metabolism of trimethoprim to a reactive iminoquinone methide by activated human neutrophils and hepatic microsomes. *J Pharmacol Exp Ther* **291**:292-299.
- Lanctot KL, Ghajar BM, Shear NH, and Naranjo CA (1994) Improving the diagnosis of hypersensitivity reactions associated with sulfonamides. *J Clin Pharmacol* **34**:1128-1233.
- Lappin MB, Kimber I, and Norval M (1996) The role of dendritic cells in cutaneous immunity. *Arch Dermatol Res* **288**:109-121.
- Lee BL, Wong D, Benowitz NL, and Sullam PM (1993) Altered patterns of drug metabolism in patients with acquired immunodeficiency syndrome. *Clin Pharmacol Ther* **53**:529-535.
- Leftwich WB (1944) An intradermal test for the recognition of hypersensitivity to the sulfonamide drugs. *Bull Johns Hopkins Hosp* **74**:26-48.
- Levenson DE, Arndt KA, and Stern RS (1991) Cutaneous manifestations of adverse drug reactions. *Immunol Allergy Clin N Amer* **11**:493-507.
- Levy M (1997) Role of viral infections in the induction of adverse drug reactions. *Drug Safety* **16**:1-8.
- Leyva L, Torres MJ, Posadas S, Blanca M, Besso G, O'Valle F, del Moral RG, Santamaria LF, and Juarez C (2000) Anticonvulsant-induced toxic epidermal necrolysis: monitoring the immunologic response. *J Allergy Clin Immunol* **105**:157-165.
- Lisi P and Stingeni L (1993) Fixed drug eruption: bullous form. *Clin Dermatol* **11**:461-466.
- Litt JZ (1999) *Drug Eruption Reference Manual*, Parthenon, New York.
- Little MC, Metcalfe JW, Healy J, Gawkrödger DJ, and MacNeil S (1998) The participation of proliferative keratinocytes in the preimmune response to sensitizing agents. *Br J Dermatol* **138**:45-56.
- Liu Y and Levy G (1998) Activation of heterocyclic amines by combinations of prostaglandin H synthase-1 and -2 with N-acetyltransferase 1 and 2. *Cancer Lett* **133**:115-123.
- Lotfin CD and Eling TE (1996) Prostaglandin synthase 2 expression in epidermal growth factor-dependent proliferation of mouse keratinocytes. *Arch Biochem Biophys* **330**:419-429.
- Malve RE and Fischer SM (1996) Multifactor regulation of prostaglandin H synthase-2 in murine keratinocytes. *Mol Carcinogen* **17**:207-216.
- Maria VAJ, Pinto L, and Victorino RMM (1994) Lymphocyte reactivity to *ex vivo* drug antigens in drug-induced hepatitis. *J Hepatol* **21**:151-158.
- Maria VAJ and Victorino RMM (1997) Diagnostic value of specific T cell reactivity to drugs in 95 cases of drug induced liver injury. *Gut* **41**:534-540.
- Martin S and Weltzien HU (1994) T cell recognition of haptens, a molecular view. *Int Arch Allergy Immunol* **104**:10-16.
- Marutani K, Otobe Y, Nagamuta M, Matsubara S, and Otani H (1998) Photoallergenicity of a fluorquinolone antibacterial agent with a fluorene substituent at the 8-position in guinea pigs exposed to long-wavelength UV light. *Skin Pharmacol Appl Skin Physiol* **11**:232-240.
- Matzinger P (1998) An innate sense of danger. *Semin Immunol* **10**:399-415.
- Matzinger P and Fuchs EJ (1996) Beyond 'self' and 'non-self': immunity is a conversation not a war. *J NIH Res* **8**:35-39.
- Mauri-Hellweg D, Bettens F, Mauri D, Brander C, Hunziker T, and Pichler WJ (1995) Activation of drug-specific CD4+ and CD8+ T cells in individuals allergic to sulfonamides, phenytoin, and carbamazepine. *J Immunol* **155**:462-472.
- Medina L, Mills J, Leoung G, Hopewell PC, Lee B, Modin G, and Benowitz N (1990) Oral therapy for *Pneumocystis carinii* pneumonia in the acquired immunodeficiency syndrome. *N Engl J Med* **323**:776-782.
- Meekins CV, Sullivan TJ, and Gruchalla RS (1994) Immunochemical analysis of sulfonamide drug allergy: identification of sulfamethoxazole-substituted human serum proteins. *J Allergy Clin Immunol* **94**:1017-1024.
- Merk H, Baron J, Hertl M, Niederau D, and Rubben A (1997) Lymphocyte activation in allergic reactions elicited by small-molecular-weight compounds. *Int Arch Allergy Immunol* **113**:173-176.
- Moore DE (1998) Mechanisms of photosensitization by phototoxic drugs. *Mutat Res* **422**:165-173.
- Moore DE and Chappuis PP (1988) A comparative study of photochemical sensitization by the non-steroidal anti-inflammatory drugs, naproxen, benoxaprofen and indomethacin. *Photochem Photobiol* **47**:173-180.
- Moore DE, Roberts-Thomson S, Dong Z, and Duke C (1990) Photochemical studies on the anti-inflammatory drug diclofenac. *Photochem Photobiol* **52**:685-690.
- Moore N, Lecointre D, Noblet C, and Mabilie M (1998) Frequency and cost of serious adverse drug reactions in a department of general medicine. *Br J Clin Pharmacol* **45**:301-308.
- Morgan ET (1997) Regulation of cytochrome P450 during inflammation and infection. *Drug Metab Rev* **29**:1129-1188.
- Morgan ET (2001) Regulation of cytochrome P450 by inflammatory mediators: why and how? *Drug Metab Dispos* **29**:207-212.
- Moser J, Bosca F, Lovell WW, Castell JV, Miranda MA, and Hye A (2000a) Photobinding of carprofen to protein. *J Photochem Photobiol B: Biol* **58**:13-19.
- Moser J, Sarabia Z, Minter H, Lovell WW, Beijersbergen GJM, and van Henegouwen B (2000b) Photobinding of ketoprofen in vitro and ex vivo. *J Photochem Photobiol B: Biol* **58**:37-45.
- Nakamura H, Utrecht J, Cribb AE, Miller MA, Zahid N, Hill J, Josephy PD, Grant DM, and Spielberg SP (1995) In vitro formation, disposition and toxicity of N-acetoxy-sulfamethoxazole, a potential mediator of sulfamethoxazole toxicity. *J Pharmacol Exp Ther* **274**:1099-1104.
- Naldi L, Conforti A, Venegoni M, Troncon MG, Caputi A, Ghiotto E, Cocci A, Moretti U, Velo G, and Leone R (1999) Cutaneous reactions to drugs. An analysis of spontaneous reports in four Italian regions. *Br J Clin Pharmacol* **48**:839-846.
- Nazareth I, Mortimer P, and McKendrick G (1972) Ampicillin sensitivity in infectious mononucleosis—temporary or permanent? *Scand J Infect Dis* **4**:229-230.
- Nickoloff BJ, Mitra RS, Green J, Zheng X-G, Shimizu Y, Thompson C, and Turka LA (1993) Accessory cell function of keratinocytes for superantigens. Dependence on lymphocyte function-associated antigen-1/intercellular adhesion molecule-1 interaction. *J Immunol* **150**:2148-2159.
- Nickoloff BJ and Turka LA (1994) Immunological functions of non-professional antigen-presenting cells: New insights from studies of T-cell interactions with keratinocytes. *Immunol Today* **15**:464-469.
- Nickoloff BJ, Turka LA, Mitra RS, and Nestle FO (1995) Direct and indirect control of T-cell activation by keratinocytes. *J Invest Dermatol* **105**:25S-29S.
- Nishioka K, Groreishi M, and Yokozeki H (1999) Heat shock proteins and skin diseases. *Curr Opin Infect Dis* **12**:171-176.
- Numm P, Kibuga D, Gatha S, Brindle R, Imalingat A, Wasunna K, Lucas S, Gilks C, Omwega M, Were J, and McAdam K (1991) Cutaneous hypersensitivity reactions due to thiacetazone in HIV-1 seropositive patients treated for tuberculosis. *Lancet* **337**:627-630.
- Nwokolo C, Byrne L, and Misch KJ (1988) Toxic epidermal necrolysis occurring during treatment with trimethoprim alone. *Br Med J* **296**:970.
- Odom RB, James WD, and Berger TG (2000) *Andrews' Diseases of the Skin*. W. B. Saunders Company, Philadelphia.
- Ohshima A, Seo N, Takigawa M, and Tokura Y (2000) Formation of antigenic quinolone photoadducts on Langerhans cells initiates photoallergy to systemically administered quinolone in mice. *J Invest Dermatol* **114**:569-575.
- O'Loughlin S, Goldman GC, and Provost TT (1978) Fate of pemphigus antibody

- following successful therapy: preliminary evaluation of pemphigus antibody determinations to regulate therapy. *Arch Dermatol* **114**:1769–1772.
- O'Neil WM, Drobitch RK, MacArthur RD, Farrough MJ, Doll MA, Fretland AJ, Hein DW, Crane LR, and Svensson CK (2000) Acetylator phenotype and genotype in patients infected with HIV: discordance between methods for phenotype determination and genotype. *Pharmacogenetics* **10**:171–182.
- Page RL, O'Neil MG, Yarbrough DR, and Conradi S (1998) Fatal toxic epidermal necrolysis related to lamotrigine administration. *Pharmacotherapy* **18**:392–398.
- Paquet P and Piérard GE (1997) Erythema multiforme and toxic epidermal necrolysis: a comparative study. *Am J Dermatopathol* **19**:127–132.
- Papakonstantinou G, Fuessl H, and Hehlmann R (1988) Trimethoprim-sulfamethoxazole desensitization in AIDS. *Klin Wochenschr* **66**:351–353.
- Patel BM (1967) Skin rash with infectious mononucleosis and ampicillin. *Pediatrics* **40**:910–911.
- Pelekanos J, Camfield P, Camfield C, and Gordon K (1991) Allergic rash due to antiepileptic drugs: clinical features and management. *Epilepsia* **32**:554–559.
- Pertel P and Hirschtick R (1994) Adverse reactions to dapsone in persons infected with human immunodeficiency virus. *Clin Infect Dis* **18**:630–632.
- Picardo M, Zompetta C, Marchese C, De Luca C, Faggioni A, Schmidt RJ, and Santucci B (1992) Paraphenylenediamine, a contact allergen, induces oxidative stress and ICAM-1 expression in human keratinocytes. *Br J Dermatol* **126**:450–455.
- Pichler WJ, Schnyder B, Zanni MP, Hari Y, and von Greyerz S (1998) Role of T cells in drug allergies. *Allergy* **53**:225–232.
- Pierfite C, Royer RJ, Moore N, and Begaud B (2000) The link between sunshine and phototoxicity of sparfloxacin. *Br J Clin Pharmacol* **49**:609–612.
- Pirmohamed M, Graham A, Roberts P, Smith D, Chadwick D, Breckenridge AM, and Park BK (1991) Carbamazepine-hypersensitivity: assessment of clinical and in vitro chemical cross-reactivity with phenytoin and oxcarbazepine. *Br J Clin Pharmacol* **32**:741–749.
- Pirmohamed M, Kitteringham NR, Guenther TM, Breckenridge AM, and Park BK (1992) An investigation of the formation of cytotoxic, protein-reactive and stable metabolites from carbamazepine in vitro. *Biochem Pharmacol* **43**:1675–1682.
- Podzamec D, Consiglio E, Ferrer E, and Gudiol F (2000) Efavirenz associated with corticosteroid in patients with previous severe hypersensitivity reaction to nevirapine. *AIDS* **14**:331–332.
- Pratt WB (1990) Drug allergy, in *Principles of Drug Action. The Basis of Pharmacology* (Pratt WB and Taylor P eds) pp 533–564, Churchill Livingstone, New York.
- Puig L, Nadal C, Fernandez-Figueras M-T, and Alomar A (1996) Carbamazepine-induced drug rashes: diagnostic value of patch tests depends on clinicopathological presentation. *Contact Dermatitis* **34**:435–437.
- Pullen H, Wright N, and Murdoch JM (1967) Hypersensitivity reactions to antibacterial drugs in infectious mononucleosis. *Lancet* **2**:1176–1178.
- Quirino T, Bonfanti P, Arcidiacono M, Pusterla L, Cagni A, Scaglione F, and Milazzo F (1999) Acetylator phenotype prevalence in HIV-infected patients without previous trimethoprim-sulfamethoxazole hypersensitivity. *Biomed Pharmacother* **53**:286–287.
- Reilly TP, Lash LH, Doll MA, Hein DW, Woster PM, and Svensson CK (2000) A role for bioactivation and covalent binding within epidermal keratinocytes in sulfonamide-induced cutaneous drug reactions. *J Invest Dermatol* **114**:1164–1173.
- Reilly TP, MacArthur RD, Farrough MJ, Crane LR, Woster PM, and Svensson CK (1999) Is hydroxylamine-induced cytotoxicity a valid marker for hypersensitivity reactions to sulfamethoxazole in HIV-infected individuals? *J Pharmacol Exp Ther* **291**:1356–1364.
- Rieder MJ, Krause R, and Bird IA (1995) Time-course of toxicity of reactive sulfonamide metabolites. *Toxicology* **95**:141–146.
- Rieder MJ, Shear NH, Kanee A, Tang BK, and Spielberg SP (1991) Prominence of slow acetylator phenotype among patients with sulfonamide hypersensitivity reactions. *Clin Pharmacol Ther* **49**:13–17.
- Rieder MJ, Utrecht J, Shear NH, Cannon M, Miller M, and Spielberg SP (1989) Diagnosis of sulfonamide hypersensitivity reactions by in-vitro "rechallenge" with hydroxylamine metabolites. *Ann Intern Med* **110**:286–289.
- Rieder MJ, Utrecht J, Shear NH, and Spielberg SP (1988) Synthesis and in vitro toxicity of hydroxylamine metabolites of sulfonamides. *J Pharmacol Exp Ther* **244**:724–728.
- Riley RJ, Cribb AE, and Spielberg SP (1991) Glutathione transferase mu deficiency is not a marker for predisposition to sulphonamide toxicity. *Biochem Pharmacol* **42**:696–698.
- Riley RJ, Kitteringham NR, and Park BK (1989) Structural requirements for bioactivation of anticonvulsants to cytotoxic metabolites in vitro. *Br J Clin Pharmacol* **28**:482–487.
- Roth DE, Spencer LV, and Ahrens EM (1989) Cutaneous reactions to drugs used for rheumatologic disorders. *Med Clin N Am* **73**:1275–1298.
- Roudier C, Caumes E, Rogeaux O, Bricaire F, and Gentilini M (1994) Adverse cutaneous reactions to trimethoprim-sulfamethoxazole in patients with the acquired immunodeficiency syndrome and *Pneumocystis carinii* pneumonia. *Arch Dermatol* **130**:1383–1386.
- Roujeau J-C (1987) Clinical aspects of skin reactions to NSAIDs. *Scand J Rheum* **65** (Suppl):131–134.
- Roujeau J-C, Guillaume J-C, Fabre J-P, Penso D, Fléchet M-L, and Girre J-P (1990) Toxic epidermal necrolysis (Lyell syndrome) *Arch Dermatol* **126**:37–42.
- Roujeau J-C, Kelly JP, Naldi L, Rzyany B, Stern RS, Anderson T, Auquier A, Bastuji-Garin S, Correia O, Locati F, Mockenhaupt M, Paoletti C, Shapiro S, Shear N, Schopf E, and Kaufman DW (1995) Medication use and the risk of Stevens-Johnson syndrome or toxic epidermal necrolysis. *New Engl J Med* **333**:1600–1607.
- Roujeau J-C and Stern RS (1994) Severe adverse cutaneous reactions to drugs. *N Engl J Med* **331**:1272–1285.
- Roy D and Snodgrass WR (1990) Covalent binding of phenytoin to protein and modulation of phenytoin metabolism by thiols in A/J mouse liver microsomes. *J Pharmacol Exp Ther* **252**:895–900.
- Salerno A and Dieli F (1998) Role of  $\gamma\delta$  T lymphocytes in immune response in humans and mice. *Crit Rev Immunol* **18**:327–357.
- Sanwo M, Nwadiuko R, and Beall G (1996) Use of intravenous immunoglobulin in the treatment of severe cutaneous drug reactions in patients with AIDS. *J Allergy Clin Immunol* **98**:1112–1115.
- Sattler FR and Remington RS (1981) Intravenous trimethoprim-sulfamethoxazole therapy for *Pneumocystis carinii* pneumonia. *Am J Med* **70**:1215–1221.
- Schlienger RC, Shapiro LE, and Shear NH (1998) Lamotrigine-induced severe cutaneous adverse reactions. *Epilepsia* **39** (Suppl 7):S22–S26.
- Schneider MME, Nielsen TL, Nelsing S, Hoepelman AIM, Schattenkerk JKME, van der Graaf Y, Kolsters AFP, and Borleffs JCC (1995) Efficacy and toxicity of two doses of trimethoprim-sulfamethoxazole as primary prophylaxis against *Pneumocystis carinii* pneumonia in patients with human immunodeficiency virus. *J Infect Dis* **171**:1632–1636.
- Schnyder B, Frutig K, Mauri-Hellweg D, Limat A, Yawalkar N, and Pichler WJ (1998) T-cell-mediated cytotoxicity against keratinocytes in sulfamethoxazole-induced skin reaction. *Clin Exp Allergy* **28**:1412–1417.
- Schnyder B, Mauri-Hellweg D, Zanni M, Bettens F, and Pichler WJ (1997) Direct, MHC-dependent presentation of the drug sulfamethoxazole to human alpha T cell clones. *J Clin Invest* **100**:136–141.
- Selvaag E (1997) Clinical drug photosensitivity: A retrospective analysis of reports of the Norwegian adverse drug reactions committee from the years 1970–1994. *Photodermatol Photoimmunol Photomed* **13**:21–23.
- Shafer RW, Seitzmann PA, and Tapper ML (1989) Successful prophylaxis of *Pneumocystis carinii* pneumonia in the acquired immunodeficiency syndrome. *J Acquir Immune Defic Syndr* **2**:389–393.
- Shear NH and Spielberg SP (1988) Anticonvulsant hypersensitivity syndrome. In vitro assessment of risk. *J Clin Invest* **82**:1826–1832.
- Shear NH, Spielberg SP, Grant DM, Tang BK, and Kalow W (1986) Differences in metabolism of sulfonamides predisposing to idiosyncratic toxicity. *Ann Intern Med* **105**:179–184.
- Shelley WB and Shelley ED (1987) Nonpigmenting fixed drug eruption as a distinctive reaction pattern: examples caused by sensitivity to pseudoephedrine hydrochloride and tetrahydrazoline. *J Am Acad Dermatol* **17**:403–407.
- Shimoda K, Ikeda T, Okawara S, and Kato M (2000) Possible relationship between phototoxicity and photodegradation of sitafloxacin, a quinolone antibacterial agent, in the auricular skin of albino mice. *Toxicol Sci* **56**:290–296.
- Shimoda K and Kato M (1998) Involvement of reactive oxygen species, protein kinase C, and tyrosine kinase in prostaglandin E2 production in Balb/c 3T3 mouse fibroblast cells by quinolone phototoxicity. *Arch Toxicol* **72**:251–256.
- Silber IB and Epstein JW (1934) The treatment of chorea with phenylethylhydantoin. *Arch Pediatr* **51**:373–382.
- Singh I, Pahan K, Khan M, and Singh AK (1998) Cytokine-mediated induction of ceramide production is redox-sensitive. Implications to proinflammatory cytokine-mediated apoptosis in demyelinating disease. *J Biol Chem* **272**:20354–20362.
- Smith CL, Brown I, and Torraca BM (1998) Acetylator status and tolerance of high-dose trimethoprim-sulfamethoxazole therapy among patients with human immunodeficiency virus. *Clin Infect Dis* **25**:1477–1478.
- Smythe MA and Umstead GS (1989) Phenytoin hepatotoxicity: a review of the literature. *DICP, Ann Pharmacother* **23**:13–18.
- Sowden JM and Smith AG (1990) Multifocal fixed drug eruption mimicking erythema multiforme. *Clin Exper Dermatol* **15**:387–388.
- Spielberg SP, Gordon GB, Blake DA, Goldstein DA, and Herlong HF (1981a) Predisposition to phenytoin hepatotoxicity assessed in vitro. *N Engl J Med* **305**:722–727.
- Spielberg SP, Gordon GB, Blake DA, Mellits ED, and Bross DS (1981b) Anticonvulsant toxicity in vitro: Possible role of arene oxides. *J Pharmacol Exp Ther* **217**:386–389.
- Spira R, Mignard M, Doutre M-S, Morlat P, and Dabis F (1998) Prevalence of cutaneous disorders in a population of HIV-infected patients. *Arch Dermatol* **134**:1208–1212.
- Stern RS and Wintroub BU (1999) Cutaneous reactions to drugs, in *Fitzpatrick's Dermatology in General Medicine* (Freedburg IM, Eisen AZ, Austen KF, Goldsmith LA, Katz SI, and Fitzpatrick TB eds) pp 1633–1642, McGraw-Hill, New York.
- Stewart RB, May FE, and Cullen SI (1979) Dermatologic adverse drug reactions in hospitalized patients. *Am J Hosp Pharm* **36**:609–612.
- Stoof FJ, Boersma DM, and Nickoloff BJ (1994) Keratinocytes and immunological cytokines, in *The Keratinocyte Handbook*, (Leigh I, Lane E, and Watt F eds) pp 365–399, Cambridge University Press, Cambridge, UK.
- Tagigawa M and Miyachi Y (1982) Mechanisms of contact photosensitivity in mice. I. T cell regulation of contact photosensitivity to tetrachlorosalicylanilide under the genetic restrictions of major histocompatibility complex. *J Invest Dermatol* **79**:108–115.
- Tennis P and Stern RS (1997) Risk of serious cutaneous disorders after initiation of use of phenytoin, carbamazepine, or sodium valproate: a record linkage study. *Neurology* **49**:542–546.
- Thune P, Eeg-Larson T, and Nilsen R (1984) Acute linear IgA dermatosis in a child following varicella. *Arch Dermatol* **120**:1237–1238.
- Todyrk SM, Melcher AA, Dalgleish AG, and Vile RG (2000) Heat shock proteins refine the danger theory. *Immunology* **99**:334–337.
- Tokura Y (1998) Quinolone photoallergy: Photosensitivity dermatitis induced by systemic administration of photohaptenic drugs. *J Dermatol Sci* **18**:1–10.
- Tokura Y, Nishijima T, Yagi H, Furukawa F, and Takigawa M (1996) Photohaptenic properties of fluoroquinolones. *Photochem Photobiol* **64**:838–844.
- Tokura Y, Satoh T, Yamada M, and Takigawa M (1991) Genetic control of contact photosensitivity to tetrachlorosalicylanilide. II. Igh complex controls the sensitivity induced by photohaptenic modified spleen cells but not epidermal cells. *Cell Immunol* **135**:195–207.
- Tokura Y, Seo N, Ohshima A, Yai H, Furukawa F, and Takigawa M (1999) Lymphocyte stimulation test with drug-photomodified cells in patients with quinolone photosensitivity. *J Dermatol Sci* **21**:34–41.

- Troost RJJ, Van Parys JAP, Hooijkaas H, van Joost T, Benner R, and Prens EP (1996) Allergy to carbamazepine: parallel in vivo and in vitro detection. *Epilepsia* **37**:1093–1099.
- Uetrecht JP (1999) New concepts in immunology relevant to idiosyncratic drug reactions: the "Danger Hypothesis" and innate immune system. *Chem Res Toxicol* **12**:387–395.
- Uetrecht JP (1992) The role of leukocyte-generated reactive metabolites in the pathogenesis of idiosyncratic drug reactions. *Drug Metab Rev* **24**:299–366.
- Uetrecht JP, Shear NH, and Zahid N (1993) N-chlorination of sulfamethoxazole and dapsone by the myeloperoxidase system. *Drug Metab Dispos* **21**:830–834.
- van der Linden PD, van der Lei J, Vlug AE, and Stricker BHCh (1998) Skin reactions to antibacterial agents in general practice. *J Clin Epidemiol* **51**:703–708.
- van der Ven AJ, Mantel MA, Vree TB, Koopmans PP, and van der Meer JW (1994) Formation and elimination of sulphamethoxazole hydroxylamine after oral administration of sulphamethoxazole. *Br J Clin Pharmacol* **38**:147–150.
- van Parijs L and Abbas AK (1998) Homeostasis and self-tolerance in the immune system: Turning lymphocytes off. *Science (Wash DC)* **280**:243–248.
- Vassileva SG, Mateev G, and Parish LC (1998) Antimicrobial photosensitive reactions. *Arch Intern Med* **158**:1993–2000.
- Vittorio CC and Muglia JJ (1995) Anticonvulsant hypersensitivity syndrome. *Arch Intern Med* **155**:2285–2290.
- von Greeyer S, Zanni MP, Frutig K, Schnyder B, Burkhardt C, and Pichler WJ (1999) Interaction of sulfonamide derivatives with the TCR of sulfamethoxazole-specific human  $\alpha\beta$  T cell clones. *J Immunol* **162**:595–602.
- Wakem P, Burns RP, Ramirez F, Zlotnick D, Ferbel B, Haidaris CG, and Gaspari AA (2000) Allergens and irritants transcriptionally upregulate CD80 gene expression in human keratinocytes. *J Invest Dermatol* **114**:1085–1092.
- Warren KJ, Boxwell DE, Kim NY, and Drolet BA (1998) Nevirapine-associated Stevens-Johnson syndrome. *Lancet* **351**:567.
- Warrington RJ, Sauder PJ, and McPhillips S (1983) Lymphocyte transformation studies in suspected hypersensitivity to trimethoprim-sulfamethoxazole. *Clin Allergy* **13**:235–240.
- Watkins WM, Mungai M, Muhia DK, Mberu EK, Gathua S, Winstanley PA, Gilks CF, and Nunn P (1996) Cutaneous hypersensitivity reactions to thiacetazone, HIV infection and thiacetazone concentrations in plasma. *Br J Clin Pharmacol* **41**:160–162.
- Weiss ME (1992) Drug allergy. *Clin Allergy* **76**:857–882.
- Weltzien HU, Moulon C, Martin S, Padovan E, Hartmann U, and Kohler J (1996) T cell responses to haptens. Structural models for allergic and autoimmune reactions. *Toxicology* **107**:141–151.
- Wetterwald E, Cleach LL, Michel C, David E, and Revuz J (1999) Nevirapine-induced overlap Stevens-Johnson syndrome/toxic epidermal necrolysis. *Br J Dermatol* **140**:980–982.
- White MV, Haddad ZH, Brunner E, and Sainz C (1989) Desensitization to trimethoprim sulfamethoxazole in patients with acquired immune deficiency syndrome and *Pneumocystis carinii* pneumonia. *Ann Allergy* **62**:177–179.
- Winston DJ, Lau WK, Gale RP, and Young LS (1980) Trimethoprim-sulfamethoxazole therapy for the treatment of *Pneumocystis carinii* pneumonia. *Ann Intern Med* **92**:762–769.
- Wojnarowska F, Whitehead P, Leigh IM, Bhogal BS, and Black MM (1991) Identification of the target antigen in chronic bullous disease of childhood and linear IgA disease of adults. *Br J Dermatol* **124**:157–162.
- Wolkenstein P, Carriere V, Charue D, Bastuji-Garin S, Revuz J, Roujeau JC, Beaufort P, and Bagot M (1995a) A slow acetylator genotype is a risk factor for sulfonamide-induced toxic epidermal necrolysis and Stevens-Johnson syndrome. *Pharmacogenetics* **5**:255–258.
- Wolkenstein P, Charue D, Laurent P, Revuz J, Roujeau JC, and Bagot M (1995b) Metabolic predisposition to cutaneous adverse drug reactions. Role in toxic epidermal necrolysis caused by sulfonamides and anticonvulsants. *Arch Dermatol* **131**:544–551.
- Wolkenstein P, Tan C, Lecoeur S, Wechsler J, Garcia-Martin N, Charue D, Bagot M, and Beaufort P (1998) Covalent binding of carbamazepine reactive metabolites to P450 isoforms present in the skin. *Chem-Biol Interact* **113**:39–50.
- Wulferink M, Gonzalez J, Goebel C, and Gleichmann E (2001) T cells ignore aniline, a prohapten, but respond to its reactive metabolites generated by phagocytes: possible implications for the pathogenesis of toxic oil syndrome. *Chem Res Toxicol* **14**:389–397.
- Yoshizawa S, Yasuoka A, Kikuchi Y, Honda M, Gatanaga H, Tachikawa N, Hirabayashi Y, and Oka S (2000) A 5-day course of oral desensitization to trimethoprim/sulfamethoxazole (T/S) in patients with human immunodeficiency virus type-1 infection who were previously intolerant to T/S. *Ann Allergy Asthma Immunol* **85**:241–244.
- Yuen AWC, Land G, Weatherley BC, and Peck AW (1992) Sodium valproate acutely inhibits lamotrigine metabolism. *Br J Clin Pharmacol* **33**:511–513.
- Zakrzewska JM and Ivanyi L (1988) In vitro lymphocyte proliferation by carbamazepine, carbamazepine-10,11-epoxide, and oxcarbazepine in the diagnosis of drug-induced hypersensitivity. *J Allergy Clin Immunol* **82**:110–115.
- Zanni MP, Mauri-Hellweg D, Brander C, Wendland T, Schnyder B, Frei E, von Greeyer S, Bircher A, and Pichler WJ (1997) Characterization of lidocaine-specific T cells. *J Immunol* **158**:1139–1148.
- Zanni MP, von Greeyer S, Schnyder B, Brander KA, Frutig K, Hari Y, Valitutti S, and Pichler WJ (1998) HLA-restricted, processing- and metabolism-independent pathway of drug recognition by human  $\alpha\beta$  T lymphocytes. *J Clin Invest* **102**:1591–1598.
- Zanni MP, von Greeyer S, Schnyder B, Mauri-Hellweg D, Brander C, Kalbermayen C, and Pichler WJ (1996) T cell reactions in patients showing adverse immune reactions to drugs. *Inflamm Res* **45** (Suppl 2):S79–S84.
- Zhou W and Moore DE (1997) Photosensitizing activity of the anti-bacterial drugs sulfamethoxazole and trimethoprim. *J Photochem Photobiol B: Biol* **39**:63–72.
- Zielinska E, Niewiarowski W, and Bodalski J (1998) The arylamine N-acetyltransferase (NAT2) polymorphism and the risk of adverse reactions to co-trimoxazole in children. *Eur J Clin Pharmacol* **54**:779–785.
- Zone JJ, Taylor TB, Meyer LJ, and Petersen MJ (1998) The 97-Kda linear IgA bullous disease antigen is identical to a portion of the extra-cellular domain of the 180-Kda bullous pemphigoid antigen, BPAg2. *J Invest Dermatol* **110**:207–210.